

# Sero-marker and Detection of Avian Leukosis and Marek's Disease Viruses in Commercial Chicken Flocks in Egypt During 2019 to 2022

Marwa Safwat\*<sup>ID</sup>, Fatma Amer<sup>ID</sup>, Marwa Ali<sup>ID</sup>, Mai M. Morsy<sup>ID</sup>, Mohamed M. Samy<sup>ID</sup>, Motaz Mohamed<sup>ID</sup>, Wafaa Mohamed<sup>ID</sup>, and Abdullah A. Selim<sup>ID</sup>

Reference Laboratory for Veterinary Quality Control on Poultry Production (RLQP), Animal Health Research Institute (AHRI), Agriculture Research Center (ARC), P.O. Box 264, Dokki, Giza 12618, Egypt

\*Corresponding author's E-mail: marwasafwat13@yahoo.com

Received: March 27, 2025, Revised: April 29, 2025, Accepted: May 25, 2025, Published: June 30, 2025

## ABSTRACT

In the poultry industry, oncogenic disease viruses result in significant financial losses. This study aimed to update incidence data in Egyptian chicken flocks from 2019 to 2022. The prevalence of Marek's disease virus (MDV) and Avian leukosis virus (ALV) was monitored during the passive surveillance program in commercial poultry flocks, including (43) breeders, (45) layers, and (7) broiler flocks during 2019-2022 in Egypt. This passive surveillance was adopted depending on molecular detection of MDV and ALV viruses using PCR tests and serological detection of ALV using ELISA test kits. The histological and post-mortem results for clinically diseased birds have been recorded in different organs, including the Liver, spleen, kidney, ovary, intestine, and brain. Ninety-five flocks were reported and tested using PCR for monitoring ALV viruses (subtypes A, B, C, D, and J) and vvMDV. Samples used for PCR were prepared from liver and spleen tissues (5 chickens/pool). The tested flocks were negative for ALV subtypes A, B, C, and D, while only two cases were positive for ALV-J (2/95, 2.1%), including one breeder flock in 2021 and one-layer flock in 2022, both from Sharqia governorate. Although the overall detection rate of vvMDV was 18.9% (18/95), breeder flocks showed the highest detection rate (25.6%), compared to layer flocks (15.6%). Furthermore, the vvMDV virus detection rate varied from one year to another, including 4/13 (30.8%), 7/43 (16.3%), 4/24 (16.7%), and 3/15 (20 %) in 2019, 2020, 2021, and 2022, respectively. The vvMDV-positive cases were reported in eight governorates, including Sharqia, Menofia, Daqahlia, Gharbia, Qualiobia, Al Beheira, Giza, and Damietta. Moreover, the study indicated that vvMDV was detected in chickens aged 5 to 61 weeks. The ELISA test was used to detect ALV antibodies serologically. The seroprevalence of ALV was 4.7% in the study area. In conclusion, among the tested samples, only two cases of ALV-J were reported in Egyptian commercial chicken flocks during 2019-2022. During the same period, vvMDV showed an 18.9% prevalence rate. Further studies are recommended to evaluate the MDV vaccination program, including vaccine quality and efficacy.

**Keywords:** Avian leukosis virus, Detection rate, Egypt, Marek's disease virus, Prevalence

## INTRODUCTION

Oncogenic disease viruses cause serious economic losses due to increased mortalities, carcass condemnation, decreased growth rates, reduced egg production, and changes in egg size and quality (Payne and Fadly, 1997). Avian leukosis viruses (ALVs) are one of the alpha retroviruses from the family Retroviridae (Zhang et al., 2020). According to the envelope gene, they are divided into six subgroups (A to E and J). All ALV subtypes are exogenous viruses that can induce B-cell malformation,

leading to lymphoma, especially in susceptible chicken species, except for subgroup E, which consists of non-oncogenic endogenous viruses (Hollmann et al., 2021). The ALVs are transmitted through multiple routes, such as vertically (via eggs) and horizontally (direct or indirect contact between birds) (Tan et al., 2024). Infected chickens may exhibit a wide range of clinical signs, including general emaciation and paleness in the comb and wattle, ruffled feathers, recumbency, and decline in egg production in layer flocks (Eid et al., 2019). Since no effective vaccines or treatments exist to control leukosis, it

is essential to identify and remove infected eggs and diseased chickens from breeding populations. In Egypt, ALV-J was confirmed in broiler breeder flocks (Arafa et al., 2007) and later spread rapidly (Kilany et al., 2015). The diagnosis of ALV infection is based on gross pathological lesions, serological, and molecular detection in infected chickens (Abdel Gayed et al., 2017).

Marek's disease (MD) is an infectious viral disease of chickens caused by the cell-associated Marek's disease virus (MDV), which belongs to the genus *Mardivirus*, subfamily *Alphaherpesvirinae*. It is also known as Gallid herpesvirus 2 (GaHV-2). There are three serotypes of MDV: MDV-1, which is pathogenic in chickens. MDV-2 and MDV-3 (herpesvirus of turkey-HVT), which are non-pathogenic and used in vaccine production (Witter and Schat, 2003).

MDV-1 strains are further classified into four pathotypes based on virulence: very virulent plus (vv+MDV), very virulent (vvMDV), virulent (vMDV), and mild (mMDV) (Witter et al., 2005).

The MDV-1 serotype is characterized by the presence of an oncogene and other unique genes, such as vIL8, PP38, and vTR, located in repeat regions, like TRL (Lee et al., 2000). Chickens are most susceptible at 4 weeks of age or older. The disease manifests in several forms in chickens, including lymphomatosis (in different organs like skin, eyes, and visceral organs), and neural form, which can cause temporary paralysis due to affection of the central nervous system (Nair, 2013).

Vertical transmission is rare, but horizontal transmission via airborne spread is well documented (Payne and Venugopal, 2000).

The first reported case of classical Marek's disease (MD) in Egypt was documented in 1953 (Soliman et al., 1954). Subsequent pathological, virological, and Sero-epidemiological studies confirmed that in Egypt. The MDV causes chicken disease complications, even in vaccinated flocks (Amin et al., 2001). Virulent MDV strains have been consistently detected in Egypt (Abdallah et al., 2018), and multiple studies by Hassanin et al. (2013) and LebDAH et al. (2017) have investigated the circulation of MDV strains in poultry flocks in Egypt. Through sequencing of the Meq protein, Abdallah et al. (2018) and Yehia et al. (2021) identified several amino acid mutations associated with MDV virulence. Several vaccines have been developed for MD control, including the Bivalent type (HVT and the serotype two strain SB-1), and the herpes virus of turkey (HVT) vaccine (Witter and Lee, 1984), or the "Rispen" vaccine (attenuated serotype one strain CVI988) (Rispen et al., 1972).

In Egypt, a bivalent vaccination strategy is recommended for broiler breeder flocks to enhance protection against virulent MDV strains (Eid et al., 2019). Polymerase chain reaction (PCR) is a rapid and reliable diagnostic tool to differentiate between vaccinated flocks and field strains of MDV serotype 1 (Handberg et al., 2001). The present study investigated the molecular prevalence of MDV and ALV using PCR and the seroprevalence of ALV (subtypes A and B) antibodies through ELISA testing. The study aimed to update incidence data in Egyptian chicken flocks from 2019 to 2022, with particular emphasis on geographical distribution patterns.

## MATERIAL AND METHODS

### Ethical approval

This study was conducted according to the guidelines of the Animal Health Research Institute (AHRI), the Agriculture Research Center (ARC), and the Ministry of Agriculture and Land Reclamation (MOALR) in Egypt.

### Flocks' history

The Reference Laboratory of Veterinary Control of Poultry Production (RLQP), Animal Health Research Institute (AHRI), Giza, Egypt, received clinically diseased and /or healthy chickens with a history of variable mortalities, a decrease in growth rate and drop in egg production, and birds showing signs of emaciation, depression, ruffled feathers associated with nervous signs like paralysis and appearance of scattered visceral tumors for disease diagnosis. All chickens, ranging in age from 1 day to 604 days, had received commercial MD vaccines upon hatching.

Between 2019 and 2022, the authors received 1,594 different samples (638 dead chickens, 478 live chickens, and 478 blood samples) representing 95 flocks (15-20 bird samples/flock) from 12 different provinces in Egypt, to investigate the two major oncogenic viruses, MDV and ALV (subtypes A, B, C, D, and J).

The flocks included 45 breeders, 43 layers, and seven broilers. The provinces were Alexandria, Ismailia, Sharqiah, Menofia, Dakahlia, Gharbia, Qualiobia, Beheira, Giza, Damietta, Kafr El Sheikh, and Minya. Only 43 out of 95 flocks tested for ALV (subtypes A and B) by ELISA test from 9 different provinces of Egypt (Sharqia, Menofia, Dakahlia, Gharbia, Qualiobia, Beheira, Giza, Kafr El Sheikh, and Minya) are shown in Table 1.

**Table 1.** Geographical distribution of tested farms during 2019-to-2022 Passive Surveillance activities in Egypt using PCR and/or ELISA test.

<sup>1</sup> GOVERNORATE	YEAR				TOTAL NO. OF TESTED		
	2019	2020	2021	2022	FARMS	<sup>2</sup> PCR USING	<sup>3</sup> ELISA
Beheira	5	7	8	9	29	29	18
Sharqiah	4	12	4	3	23	23	10
Menofia	0	8	1	0	9	9	3
Giza	0	3	4	0	7	7	3
Dakahilia	0	3	0	3	6	6	1
Qualiobia	1	1	3	0	5	5	4
Minya	0	2	2	0	4	4	2
Gharbia	1	2	0	0	3	3	1
Damietta	1	2	0	0	3	3	0
Kafr El Sheikh	1	2	0	0	3	3	1
Ismailia	0	0	2	0	2	2	0
Alexandria	0	1	0	0	1	1	0
Total	13	43	24	15	95	95	43

<sup>1</sup>The study covered 12 governorates from Egypt during the period 2019 to 2022. <sup>2</sup>PCR tests: Polymerase Chain Reaction test. <sup>3</sup>ELISA test: Commercially available Enzyme-linked immunosorbent Assay obtained from IDEXX.

#### Post-mortem examination and sample collection

Fifteen to twenty chickens from each flock were received at RLQP-AHRI for testing. The post-mortem examination for the received chickens was adapted according to RLQP standard operating procedures and protocols. Tissue specimens were directly collected from diseased organs, including the liver and spleen. They were collected and preserved frozen at -20°C until used for DNA extraction and PCR detection of the oncogenic viruses.

Ten to twenty blood samples from the wing veins of the available live birds admitted to the laboratory were taken using sterile 3 ml syringes and serum separation (centrifuged at 1000-2000 rpm). The serum was stored at -20°C in 2 ml collection tubes for ELISA serological testing.

#### Histopathological findings

For histopathological studies, tissue samples were directly collected from diseased organs, including the liver, spleen, lung, kidney, duodenum, intestine, proventriculus, brain, and ovary, and were preserved using 10% neutral-buffered formalin for an average of 3-4 days at room temperature.

#### Serological detection using the ELISA test

A total of 478 Sera samples (10-20 samples per flock) were collected from 43 chicken flocks (19 breeders and 24 layers) and tested for antibody detection against ALV

(subtype A and B) using commercial antibody ELISA (IDEXX Laboratories, Inc., Maine, USA).

#### Molecular detection by PCR

The tissue samples from 95 chicken flocks were collected, prepared, and examined using PCR tests for different oncogenic viruses (MDV and ALV subtypes A, B, C, D, and J). Organ samples showing gross pathological lesions were selected from birds that had been previously examined. Only five chicken samples from each farm were pooled and treated as a single case sample. Briefly, the tissue was homogenized after being suspended in sterile phosphate-buffered saline (PBS) and centrifuged at 3000 rpm at 4°C for 15 minutes to obtain the supernatants. The specimens were stored at -20 °C until use, and DNA extraction was performed according to (Murray and Thompson, 1980).

#### Extraction of viral Nucleic acid

Tissue homogenate samples were subjected to whole nucleic acid extraction using the QIAamp MiniElute Virus Spin Kit (Qiagen, GmbH, Germany). Briefly, 200 µL of the sample suspension was treated with 25 µL of Qiagen protease and 200 µL of AL buffer for 15 min at 56°C. After incubation, 250 µL of absolute ethanol was added to the lysate. The sample was then purified by centrifugation following the manufacturer's instructions. DNA was eluted using 100 µL of elution buffer and stored at -20°C for further analysis.

### Amplification of viral nucleic acid using conventional PCR

PCR was performed using specific primers supplied by Metabion (Germany). The nucleotide sequences are listed in Table 2.

#### PCR amplification

A 25 µL total reaction mixture contained 12.5 µL of EmeraldAmp Max PCR Master Mix (Takara, Japan), 1 µL of each primer (20 pmol concentration), 5.5 µL of nuclease-free water, and 5 µL of DNA template. The process was performed using a Thermo Cycler 2720 (Applied Biosystems). About ALV A, B, C, and D, initial denaturation was performed at 94°C for 4 min, followed by 35 cycles of denaturation at 94°C for 30 s, annealing at 55°C for 30 s, and extension at 72°C for 30 s, with a final elongation at 72°C for 10 min (Fenton et al., 2005;

Silva et al., 2007). For ALV J, the initial denaturation was conducted at 95°C for 5 min, followed by 35 cycles of 95°C for 30 s, annealing at 60°C for 30 s, and extension at 72°C for 30 s, with a final extension at 72°C for 10 min (Smith et al., 1979). The PCR conditions for MDV included one cycle of initial denaturation at 95°C for 15 min, 40 cycles of denaturation at 95°C for 45 s, annealing at 50°C for 45 s, extension at 72°C for 1 min, and a final extension at 72°C for 10 min (Handberg et al., 2001).

After amplification, the PCR products were separated by electrophoresis on a 1.5% agarose gel (AppliChem, Germany, GmbH) at 5 V/cm. For gel analysis, 15 µL of the PCR products were loaded into each well. Fragment sizes were determined using a 100 bp DNA ladder (Fermentas, Germany). The gel was imaged using a gel documentation system (Alpha Innotech, Biometra), and the data were analyzed using computer software.

**Table 2.** Primer nucleotide sequences are used for avian leukosis viruses (ALV) and Marek's disease virus in Egypt

Agent	Primer sequence (5'-3')	Amplified Product (bp)	Reference
ALV- A	H5-F GGATGAGGTGACTAAGAAAG EnvA-RAGAGAAAGAGGGGYGTCTAAGGAGA	694	Fenton et al. (2005)
ALV-B and D	BD-F CGAGAGTGGCTCGCGAGATGG BD-R AGCCGGACTATCGTATGGGGTAA	1100	Silva et al. (2007)
ALV-C	C-F CGAGAGTGGCTCGCGAGATGG C-R CCCATATACCTCCTTTTCCTCTG	1400	Silva et al. (2007)
ALV-J	H5-F GGATGAGGTGACTAAGAAAG H7-R CGAACCAAAGGTAACACACG	545	Smith et al. (1979)
MDV	ICP4 F GGATCGCCCAACACGATTACTACC ICP4 RACTGCC TCACACAACCTCATC TCC	434	Handberg et al. (2001)

## RESULTS

### Clinical and gross findings

Diseased chickens showed general signs of depression, stunted growth, prominent sternums, and mortality, reduced egg production in layers and breeders, and ruffled feathers in some birds; some affected flocks had neural lesions, such as paralysis of the legs, wings, and neck. In the case of ALV, the affected birds showed visceral tumors, diffuse or white nodules in the heart, proventriculus, liver, spleen, bursa of Fabricius, gonads, and kidney, and some birds had marked hepatosplenomegaly. For MD, the gross lesion was distinguished by congestion, hemorrhages, and splenomegaly with a nodular liver lesion and a sprain of the limb nerve.

### Histopathological findings

Histological sections were prepared from different organs (liver, spleen, ovary, kidneys, intestines, and brain) from suspected cases and were submitted for

histopathological examination. Most examined cases showed variable pathological alterations, ranging from mild inflammatory features to obvious neoplastic changes in confirmed cases.

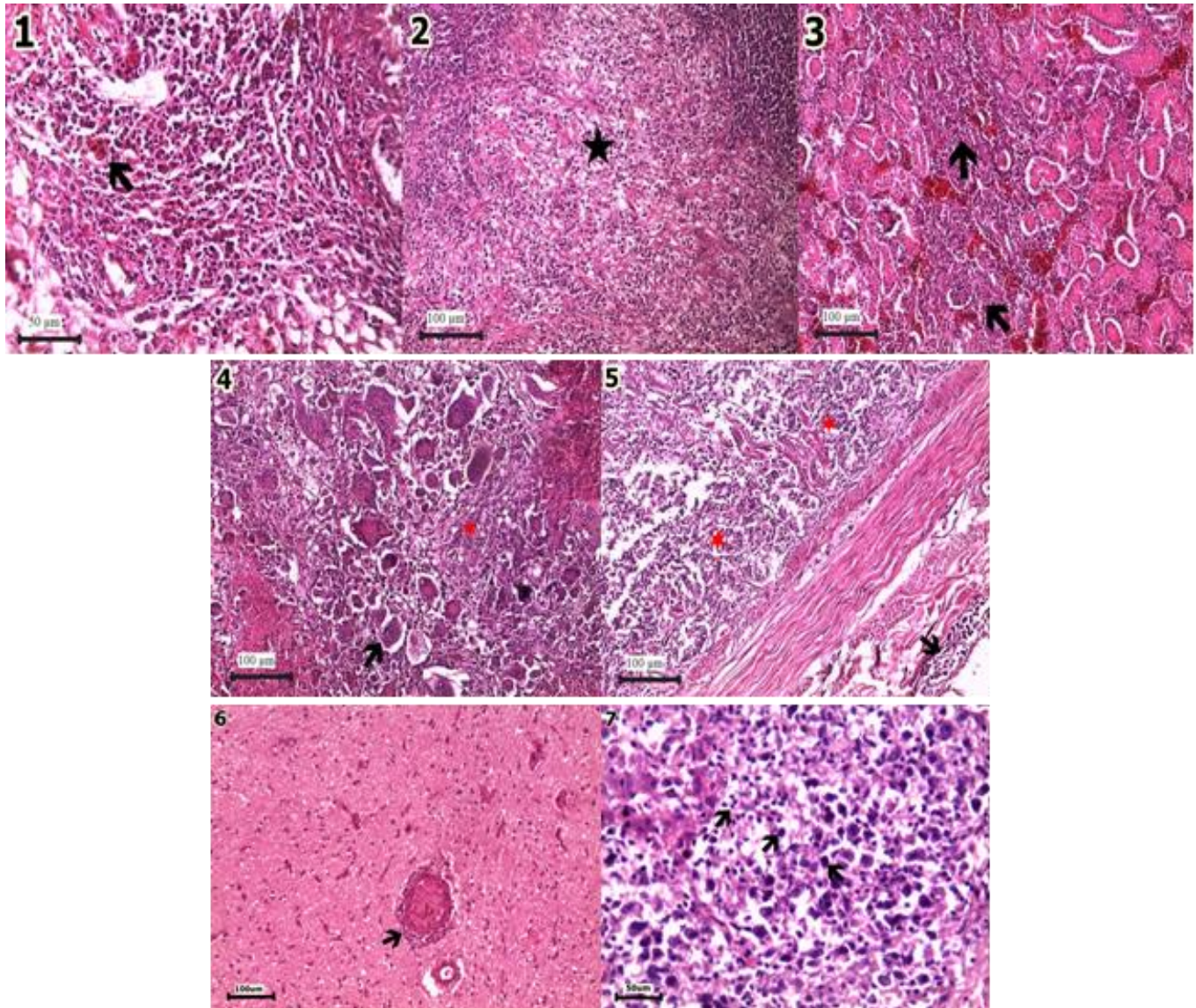
In the case of ALV-J infection, examined organs (liver, spleen, kidney, ovary, and intestine) showed severe characteristic uniform lymphocytic and myelocytic cell infiltration. The liver revealed severe congestion of hepatic sinusoids and severe destruction of hepatocytes, which were replaced by diffuse lymphocytic and myelocytic cell infiltration, though one case showed only moderate hepatocellular necrosis with extensive lymphocytic cell infiltration (Figure 1.1). The spleen showed lymphocytic cell depletion and massive tumor lymphocytic cell infiltration associated with marked fibrous tissue proliferation (Figure 1.2). Kidneys revealed massive hemorrhages and intertubular lymphocytic cells infiltration with diffuse tubular degeneration and necrosis (Figure 1.3). The ovary was characterized by severe adenocarcinoma with abundant eosinophilic cells and tumor lymphocytic cell infiltration (Figure 1.4). The



intestine revealed marked lymphocytic cell infiltration within the lamina propria with marked destruction of intestinal villi as well as a damaged muscular layer, which was replaced by massive lymphocytic cells (Figure 1.5).

The histopathological lesions of organs (brain and liver) suffering from MDV infection showed diffuse pleomorphic lymphocytic cell infiltration. The brain

showed obvious perivascular cuffing, which was mild (Figure 1.6). The liver showed hepatocyte congestion, degeneration, infiltration of mononuclear cells, vasogenic edema, cell swelling, hyaline casts in renal tubules, and lymphoproliferative foci-diffuse necrosis, which infiltrated with pleomorphic lymphocytic cells mixed with fine fibrous tissue (Figure 1.7).



**Figure 1.** The histopathological analysis of infected chickens with ALV-J. **1:** liver tissue showed diffuse infiltration of lymphocytic cells and marked myelocytic cells (arrow), **2:** spleen with marked lymphocytic depletion and tumor cells infiltration mixed with fine fibrous tissue (star), **3:** kidney revealed marked nephrosis with intertubular lymphocytic cells infiltration, **4:** ovary showed disuse destruction and necrosis of ovarian parenchyma with marked adenocarcinoma and infiltration of lymphocytic cells and giant cells, **5:** intestine showed severe enteritis with massive submucosal infiltration of lymphocytic cells (arrow) and within necrotic villi (star). The histopathological analysis of an infected chicken with MDV; **6:** brain tissue showed marked perivascular cuffing (arrow) and gliosis; **7:** hepatic tissue infiltrated with diffuse massive pleomorphic tumor cells (arrow). Hematoxylin and eosin stain (H&E).

### Molecular detection using conventional PCR

A PCR assay was used to test 95 flocks of chickens from various production types (43 breeders, 45 layers, and seven broilers) for the molecular detection of MDV and ALV subtypes A, B, C, D, and J. The samples were taken from 2019 to 2022 (Table 3); only two flocks were positive (2/95), 2.1 % for the ALV-J virus, one breeder farm in 2021, and one-layer farm in 2022 from Sharqia governorate (Table 4).

The overall incidence of MDV during the study period was 18/95 (18.9%). The highest prevalence rate recorded among different years of the study was 30.8% in 2019, followed by 20% in 2022, 16.7% in 2021, and 16.3% in 2020, as shown in Table 3. The MDV prevalence rate in breeder flocks was 25.6%, while it was 15.6% in layer flocks; all broiler flocks were negative for MDV by PCR (Table 3). The MDV geographic prevalence was 66.7% (8/12) (Sharqia, Menofia, Dakahilia, Gharbia,

Qualiobia, Beheira, Giza, Damietta) during the study period (2019 to 2022) (Table 4 and Figure 2). The age of MDV positivity in breeder flocks ranged from 35- 427 days (5-61 weeks), while for the case of the layer, flocks ranged from 60- 302 days (8.5-43 weeks) (Tables 5 and 6).

### Serological investigation

Only 43 flocks (19 breeders and 24 layers) with a total of 478 sera samples were examined for antibodies against avian leukosis virus subgroups A and B (ALV) using a commercial ELISA test; samples were collected between 2019 and 2022 from 9 provinces. From 43 tested flocks, antibodies were detected in only two breeder flocks at age 61 weeks from Beheira governorate, with seroprevalence rates of 4.7% (2/43). The two flocks showed a 100% positivity rate, with a geometric mean (GMT) of 2848 and 1892, and the coefficient variation (CV) was 18 and 24, respectively.

**Table 3.** The positive flocks of Marek's disease virus during the 2019 -2022 passive surveillance program using PCR tests among different production sectors

Year	Number of Positive Farms/ Production Sectors (Pos/Total Tested)			*Yearly positivity rate
	Breeder	Layer	Broiler	
2019	1/1	3/12	0	4/13 (30.8%)
2020	5/20	2/18	0/5	7/43 (16.3%)
2021	4/14	0/9	0/1	4/24 (16.7%)
2022	1/8	2/6	0/1	3/15 (20 %)
**Sector Incidence	11/43 (25.6%)	7/45 (15.6%)	0/7	18/95 (18.9%)

\*Yearly positivity rate: Shows the result of examined and positive flocks of MDV distribution from 2019 -2022 by PCR test during the passive surveillance program for oncogenic viruses in Egypt. \*\*Sector Incidence: This shows the detection and distribution rate of MDV-positive flocks in relation to the production sectors.

**Table 4.** Geographical distribution of examined and positive flocks of Mark's Disease Virus and Avian Leukosis Virus-j by PCR during 2019-2022 in Egypt

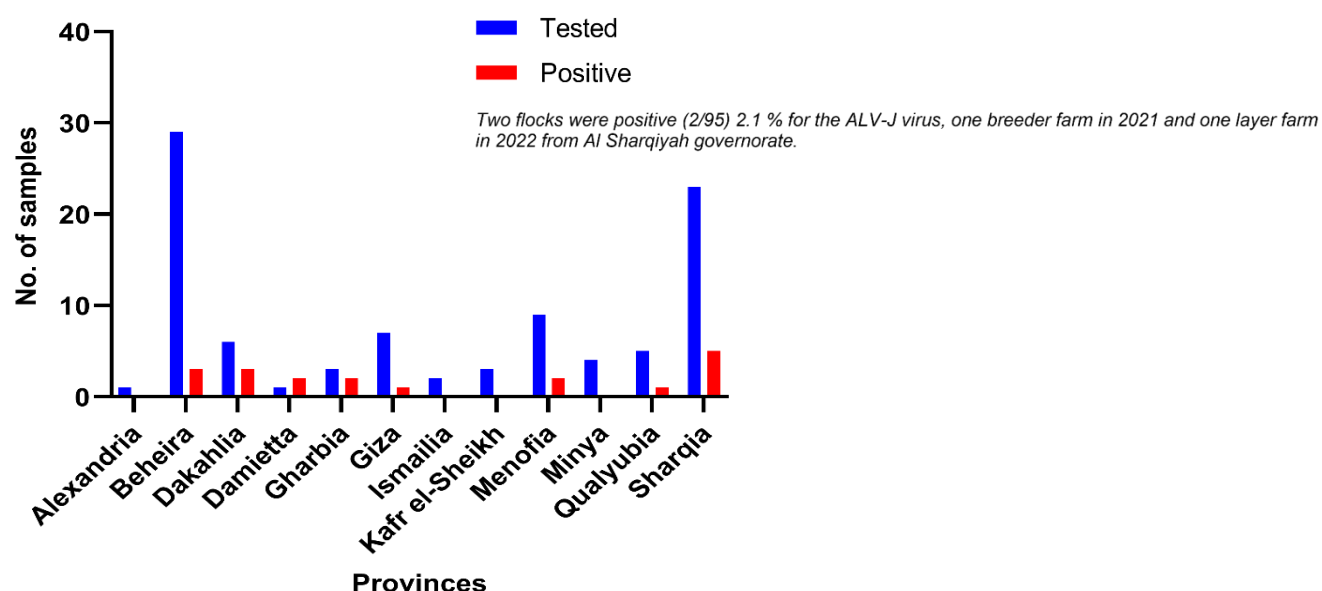
Governorate	Positive/Total Examined Farms	Positivity (%)
Alexandria	0/1	0
Ismailia	0/2	0
Sharqiah	*5/23	21.7%
Menofia	2/9	22.2%
Dakahilia	3/6	50%
Gharbia	2/3	66.7%
Qualiobia	1/5	20%
Beheira	3/29	10.3%
Giza	1/7	14.3%
Damietta	3/3	100%
Kafr El Sheikh	0/3	0
Minya	0/4	0
Total	20/95	21.1%

\*Only two flocks were detected as positive (2/95) (2.1 %) for the ALV-J virus, one breeder farm in 2021, and one-layer farm in 2022, from Sharqiah governorate.

**Table 5.** Age distribution of positive Mark's Disease Virus flocks during 2019-2022 passive surveillance in Egypt

Age / Day	$\geq 100$	100-200	200-300	$\leq 300$	Total
Type of production					
Breeder	2	-	5	4	11
Layer	1	3	2	1	7
Total	3	3	7	5	18

All tested broiler cases were negative for MDV during the study time.

**Figure 2.** Geographical distribution of examined and positive flocks of Mark's Disease Virus (MDV) and Avian Leukosis Virus -J (ALV-J) by PCR during 2019-2022 in Egypt**Table 6.** Descriptive data for 18 farms positive for Marek's Disease Virus and two farms positive for Avian Leukosis Virus-j by PCR test in Egypt during 2019-to-2022, passive surveillance

Flock ID	Year	Governorate	Age (Day)	Type of production	ELISA
1	2019	Sharqia	60	Layer	NEG
2			198	Layer	NEG
3		Gharbia	216	Layer	*ND
4		Damietta	218	breeder	ND
5	2020	Damietta	378	breeder	ND
6			399	breeder	ND
7		Menofia	210	Breeder	ND
8			35	breeder	ND
9		Sharqia	302	Layer	ND
10		Dakahilia	301	breeder	ND
11		Gharbia	216	Layer	NEG
12			427	breeder	POS
13	2021	Beheira	215	breeder	NEG
14		Qalyubia	273	breeder	NEG
15		Giza	35	breeder	NEG
16	2022	Dakahilia	120	Layer	ND
17			154	Layer	NEG
18		Beheira	280	breeder	NEG
19**	2021		80	breeder	ND
20**	2022	Sharqia	201	Layer	NEG

\*Nd: Not done means blood samples were not collected. Pos: Positive – Neg: Negative. \*\* Farm positive for ALV-J by PCR test.

## DISCUSSION

Oncogenic viruses, Marek's disease virus (MDV) and avian leukosis viruses (ALVs), are important neoplastic diseases that cause significant economic losses in the poultry industry due to immunosuppression, including chicken condemnation (Witter and Schat, 2003).

The current study offers updates on the molecular prevalence of MD and ALV subtypes A, B, C, D, and J, and antibody detection against ALV subtypes A and B in commercial chicken flocks during 2019-2022. Clinical signs in most studied cases included loss of body weight and thin abdomens with protruding sternums. The recorded gross lesions consisted of diffusion of focal tumors in different visceral organs, which appeared as white nodules in the spleen, liver, kidney, pancreas, lung, heart, proventriculus, and ovary with marked hepatosplenomegaly. The same clinical signs and gross lesions were recorded (Liu *et al.*, 2019; Eid *et al.*, 2019). Histopathological findings of ALV-J and MDV infection in different organs were previously recorded by Liu *et al.* (2019); Fotouh *et al.* (2020); Soliman *et al.* (2023).

PCR is a suitable technique to determine the serotype specificity of ALV and to differentiate between vaccinal and field strains of MDV serotype-1 (Handberg *et al.*, 2001; Silva *et al.*, 2007). From 2019 to 2022, eighteen MDV cases and two ALV-J cases were detected by PCR in 95 Egyptian chicken farms, revealing the circulation of both viruses among commercial poultry flocks during the study period.

ALVs are serious oncogenic viruses that induce severe economic losses in the poultry industry in Egypt (Mousa and Abdel-Wahab, 2009; Yehia *et al.*, 2021). Two flocks were positive (2/95), 2.1% for the ALV-J virus, one breeder farm in 2021, and one layer farm in 2022, from Sharqia governorate.

These results are consistent with Soliman *et al.* (2023), who reported that 1 of 6 breeder flocks (16.6%) in Sharqia governorate tested positive for ALV-J. However, Fotouh *et al.* (2024) detected 43 out of 57 positive samples (75.4%) from broiler flocks in Sharqia, Dakahlia, and Qalyubia Egyptian governorates from 2021 to 2023. ALVs are transmitted through multiple routes, including vertical transmission (hen to offspring) and horizontal transmission via direct or indirect contact between infected and healthy birds (Titan *et al.*, 2024). Additionally, contamination of commercial Marek's disease vaccines with avian leukosis viruses has been documented as an important source of infection in

vaccinated chickens (Silva *et al.*, 2007; Mohamed *et al.*, 2010).

MDV was detected in 18 out of 95 samples from 8 different provinces of Egypt from 2019 to 2022; 11/43 (25.6%) were breeders, and 7/45 (15.6%) were layers. All broiler flocks were negative for MDV by PCR test. The results agree with Ewies *et al.* (2020), who detected MDV in 5 out of 10 samples from 6- to 8-month-old vaccinated layer chicken farms from 6 governorates of Egypt from January 2019 to November 2020 and agree with Yehia *et al.* (2021), who detected MDV in 28 out of 40 samples from vaccinated layer and breeder chicken farms from 8 governorates of Egypt in 2020. In the current study, the detection of MDV field strains was differentiated from MDV-vaccinated strains by PCR test. The MDV-positive flocks were detected in 8 different governorates of Egypt: Sharqia, Menofia, Dakahlia, Gharbia, Qualiobia, Beheira, Giza, and Damietta, showing a high geographical prevalence rate of 66.7% (8/12). Moreover, the incidence rates of MDV vary from one governorate to another and range from 100% in Damietta to a minimum of 10.3% in Beheira governorate. MDV was previously detected in the same governorates (El-Kenawy and El-Tholoth, 2019; Ewies *et al.*, 2020; Yehia *et al.*, 2021).

The apparent age of positive Marek's disease virus cases among breeder chicken flocks ranged from 35 to 427 days (5 to 61 weeks), and the most recorded positive flocks were at age 30-61 weeks. This complies with Zhuang *et al.*, (2015), who confirmed an outbreak of Marek's disease in a vaccinated breeder flock during its highest egg-production period (24<sup>th</sup> and 30<sup>th</sup> weeks) in China. The age of Marek's disease virus-positive cases among layer flocks ranged from 60 to 302 days (8.5 to 43 weeks). Additionally, the most recorded positive flocks were from 14 to 43 weeks. This corresponds with Ewies *et al.* (2020), who identified MDV in vaccinated layer chickens aged between 24 and 32 weeks. Furthermore, the disease was demonstrated in chickens aged 3-4 weeks or older and is usually recorded between 12 and 30 weeks of age (OIE, 2010).

Marek's disease virus is one of the most transmissible diseases of fast lymphoproliferative changes in affected chickens. Although the Egyptian hatcheries follow an intensive MDV vaccination policy on the first day of age, the flocks still suffer from many cases of MDV infection, shedding, and subclinical virus circulation, which continues in farms. The vaccine breaks may occur due to the expanded virulence of MDV strains, which have developed the capability to vanquish immune responses



convinced by vaccine application (Witter, 1997; Hassanin et al., 2013), the presence of immunosuppressive agents (Haridy et al., 2009; López-Osorio et al., 2017; Umar et al., 2017) or the challenges associated with the vaccine handling due to its cell-associated form, the attenuation procedure, and the incorrect dose and route of administration (Jarosinski et al., 2006; Geerligs et al., 2008; Abdul-Careem et al., 2014).

In recent years, Egypt has reported numerous cases of isolation of virulent and highly virulent plus MDV strains from immunized chickens. Many studies have documented the isolation of a very virulent strain of MDV type 1 from many poultry flocks that have been MDV-vaccinated (El-kenawy et al., 2019; Ewies et al., 2020; Yehia et al., 2021). The widespread use of vaccines may contribute to increased virulence in field strains. While vaccines protect chickens from clinical disease, they allow the virus to replicate and spread (Haq et al., 2013; Padhi and Parcells, 2016; Mescolini et al., 2020).

While sequencing the Meq proteins, Abdallah et al. (2018) and Yehia et al. (2021) from Egypt identified several mutations in amino acids associated with MDV virulence. Moreover, the direct proliferation that occurred in lymphocytes caused tumors because of Meq gene changes, which appear to be linked to increased virulence (Lupiani et al., 2004; Shamblin et al., 2004). The virulence of MDV has increased in recent years, and moreover, some recently isolated (vv and vv+) strains have been reported as more virulent for chickens than the previously isolated strains.

The severity of the disease varies, attributable to the viral genome mutation, which can generate novel pathotypes capable of evading vaccine-induced immunity. Yehia et al. (2021) found a low amino acid identity (as low as 82.5%) between field strains and vaccine strains (CVI988 and 3004), suggesting that current vaccines may have reduced efficacy in Egypt and highlighting the need for further research.

The enzyme-linked immunosorbent assay (ELISA) is a valuable tool for surveillance, enabling the detection of exogenous ALV infections in flocks. It can also identify subgroup-specific ALVs for eradication programs, allowing the removal of infected or carrier chickens. ELISA is sensitive, safe, rapid, and suitable for large-scale testing (Abdel Gayed et al., 2017). None of the 43 farms tested in this study had detectable antibodies against ALV (subtypes A and B), except for two breeder farms in Al Beheira governorate (61-week-old birds). Abdel Gayed et al. (2017) conducted serological

studies on avian leukosis virus in broiler chickens in Egypt.

Avian leukosis virus subgroups A and B can persist in egg and meat-type chickens, often without causing significant economic losses. However, co-circulation of ALV and MDV may exacerbate disease severity compared to single infections (Wang et al., 2020).

## CONCLUSION

The results demonstrate the sporadic incidence of only two cases of ALV-J, alongside a high prevalence of vvMDV (18.9%) in Egyptian commercial chicken flocks during 2019-2022. These findings underscore the urgency for further research to examine the genetic correlation of the circulating vvMDV strains and the currently used MDV vaccines. Furthermore, the authors recommend reviewing the current MDV vaccination program, including vaccine quality and efficacy, as well as maintaining the passive reporting program for oncogenic viruses for continuous monitoring.

## DECLARATIONS

### Acknowledgments

The authors gratefully acknowledge the Reference Laboratory for Veterinary Quality Control on Poultry Production (RLQP), Animal Health Research Institute (AHRI), and Agriculture Research Center (ARC), Dokki, Giza, Egypt, for providing the facilities and support necessary to conduct this study.

### Authors' contributions

Marwa Safwat contributed to the manuscript idea, serological testing, data analysis, and manuscript writing. Fatma Amer conducted the PCR and wrote the manuscript. Marwa Ali was responsible for epidemiological data collection, sorting, analysis, and histopathology. Mai M. Morsy conducted serology testing. Mohamed M. Samy conducted post-mortem, sample collection, sorting, preparation, and storage of field samples. Motaz Mohamed was responsible for field visits and sample collection. Both Wafaa Mohamed and Abdullah A. Selim designed the study, wrote the manuscript, and revised it. All authors read and approved the final version of the manuscript.

### Availability of data and materials

The original contributions presented in the study are included in the article and will be available upon reasonable request from the corresponding author.

## Competing interests

The authors declare no competing interests.

## Ethical considerations

The authors confirm that this manuscript represents original study results that have not been previously published. All authors have reviewed and approved the manuscript before submission.

## Funding

This study was funded by institutional funding from the Reference Laboratory for Veterinary Quality Control on Poultry Production (RLQP), Animal Health Research Institute (AHRI), and Agriculture Research Center (ARC).

## REFERENCES

- Abdallah F, Hassnain O, Attar E, Ali H, Megahed M, and Nair V (2018). Marek's disease virus in Egypt: Historical overview and current research based on the major MDV-encoded oncogene Meq. *Hosts and Viruses*, 5(3): 35-43. DOI: <http://www.doi.org/10.17582/journal.hv/2018/5.3.35.43>
- Abdel Gayed MB, Tamam SM, Elkhawaga AI, and Hassan MH (2017). Serological and molecular studies on avian leucosis virus in broiler chicken in Egypt. *Viral diseases. poultry department-animal health research institute, Egypt*. Available at: [https://en.engormix.com/poultry-industry/viral-diseases-poultry/serological-molecular-studies-avian\\_a40456/](https://en.engormix.com/poultry-industry/viral-diseases-poultry/serological-molecular-studies-avian_a40456/)
- Amin A, Aly M, El Sawy A, Tanious N, Khafagy A, and Ahmed AAS (2001). Seroepidemiological and virological studies on virus-induced tumors in chickens in Egypt. *Veterinary Medicine Journal*, 49(2): 237-247. Available at: [https://vmjg.journals.ekb.eg/article\\_372110\\_3e7f76eea69ea0a23954dd992b8f5f79.pdf](https://vmjg.journals.ekb.eg/article_372110_3e7f76eea69ea0a23954dd992b8f5f79.pdf)
- Arafa A, Hussein HA, Shalaby MA, and Aly MM (2007). Serological and infection profiles of avian leukosis virus subgroup J in one-day-old chicks of broiler breeder chickens and their relatedness to virus vertical transmission. *Egyptian Journal of Virology*, 4: 41-50. Available at <https://scholar.cu.edu.eg/?q=mshalaby/publications>
- Eid AE, Abd Ellatieff HA, Ellakany HF, Abou-Rawash AR, and Abd El-Hamid HS (2019). Studies on tumor disease viruses in chickens in Egypt. *Alexandria Journal of Veterinary Sciences*, 60: 184-195. Available at: <https://www.cabidigitallibrary.org/doi/full/10.5555/20193096966>
- El-Kenawy A, Emad A, and El-Tholoth M (2019). Isolation and identification of Marek's disease virus (MDV) from feather follicle epithelium and internal organs of diseased chickens in Dakahlia Governorate, Egypt. *Mansoura Veterinary Medical Journal*, 20(2): 6-11. DOI: <https://www.doi.org/10.21608/mvmj.2019.22.102>
- Ewies S, Mady W, Hamad E, Arafa A, Tamam S, and Madbouly H (2021). Isolation and molecular characterization of Marek's disease virus from layer chickens in Egypt. *Journal of Veterinary Medical Research*, 27(2): 168-176. DOI: <https://www.doi.org/10.21608/JVMR.2021.59613.1032>
- Fenton SP, Reddy MR, and Bagust TJ (2005). Single and concurrent avian leukosis virus infections with avian leukosis virus-J and avian leukosis virus-A in Australian meat type infections with avian leukosis virus-J and avian leukosis virus-A in Australian meat-type chickens. *Avian Pathology*, 34: 48-54. DOI: <https://www.doi.org/10.1080/03079450400025356>
- Fotouh A, Soufy H, El-Begawey MB, and Nasr SM (2020). Pathological, clinicopathological and molecular investigations on chickens experimentally infected with avian leucosis virus type J. *Advanced Animal Veterinary Science*, 8(6): 590-600. DOI: <http://www.doi.org/10.17582/journal.aavs/2020/8.6.590.600>
- Fotouh A, Shosha EAE, Zanaty AM, and Darwesh MM (2024). Immunopathological investigation and genetic evolution of Avian leukosis virus Subgroup-J associated with myelocytomatosis in broiler flocks in Egypt. *Virology Journal*, 21(1): 83. DOI: <https://www.doi.org/10.1186/s12985-024-02329-7>
- Geerligs H, Quanz S, Suurland B, Spijkers IEM, Rodenberg J, Davelaar FG, Jongsma B, and Kumar M (2008). Efficacy and safety of cell associated vaccines against Marek's disease virus grown in a continuous cell line from chickens. *Vaccine*, 26(44): 5595-5600. DOI: <https://www.doi.org/10.1016/j.vaccine.2008.07.080>
- Gong Z, Zhang K, Li L, Wang H, Qiu Y, Li I, Hou G, Yu J, Wang J, and Shan H (2014). Effect of vaccination with different types and dosages against a very virulent Marek's disease virus strain. *Journal of Molecular and Genetics Medicine*, 8: 1-5. DOI: <https://www.doi.org/10.4172/1747-0862.1000144>
- Handberg KJ, Nielson OL, and Jorgensen PH (2001). Use of serotype1 and serotype 3 specific polymerase chain reaction for the detection of Marek's disease virus in chickens. *Avian Pathology*, 30(3): 243-249. DOI: <https://www.doi.org/10.1080/03079450120054659>
- Haq K, Schat KA, and Sharif S (2013). Immunity to Marek's disease: Where are we now?. *Development and Comparative Immunology*, 41(3): 439-446. DOI: <https://www.doi.org/10.1016/j.dci.2013.04.001>
- Haridy M, Goryo M, Sasaki J, and Okada K (2009). Pathological and immunohistochemical study of chickens with co-infection of Marek's disease virus and chicken anaemia virus. *Avian Pathology*, 38: 469-483. DOI: <https://www.doi.org/10.1080/03079450903349162>
- Hassanin O, Abdallah F, and El-Araby IE (2013). Molecular characterization and phylogenetic analysis of Marek's disease virus from clinical cases of Marek's disease in Egypt. *Avian Disease*, 57(2 SI): 555-561. DOI: <https://www.doi.org/10.1637/10337-082912-Reg.1>
- Hollmann, Nancy P, Cardoso, Juan C, Espeche, Paulo C, and Maffia (2021). Review of antiviral peptides for use against zoonotic and selected non-zoonotic viruses. *Peptides*, 142: 170570. DOI: <https://www.doi.org/10.1016/j.peptides.2021.170570>

- Kilany WH, Soliman MA, Safwat M, Mehana O, El-Magid MA, Marwa AE, Hassan MK and Nasif SA (2015). Detection of avian leukosis virus subgroup J from commercial Peking duck breeder farm in Egypt. *International Journal of Virology*, 11(3): 139-145. DOI: <https://www.doi.org/10.3923/ijv.2015.139.145>
- Lebdah MA, Nassif AS, Shahein MA, and El-Basrey Y (2017). Isolation and identification of very virulent strains of Marek's disease virus from MDV-vaccinated flocks in Egypt. *Zagazig Veterinary Journal*, 45(3): 197-205. DOI: <https://www.doi.org/10.21608/zvjz.2017.7947>
- Lee SI, Takagi M, Ohashi K, Sugimoto C, and Onuma M (2000). Difference in the meq gene between oncogenic and attenuated strains of Marek's disease virus serotype 1. *Journal of Veterinary Medicine*, 62(3): 287-292. DOI: <https://www.doi.org/10.1292/jvms.62.287>
- Liu H, Ma K, Liu M, Yang C, Huang X, Zhao Y, and Qi K (2019). Histologic findings and viral antigen distribution in natural coinfection of layer hens with subgroup J avian leukosis virus, Marek's disease virus, and reticuloendotheliosis virus. *Journal of Veterinary Diagnostic Investigation*, 31(5): 761-765. DOI: <https://www.doi.org/10.1177/1040638719868274jvdi.sagepub.com>
- López-Orsorio S, Piedrahita D, Espinal-Restrepo MA, Ramírez-Nieto GC, Nair V, Williams SM, Baigent S, Ventura-Polite C, Aranzazu-Taborda DA, and Chaparro-Gutiérrez JJ (2017). Molecular characterization of Marek's disease virus in a poultry layer farm from Colombia. *Poultry Science*, 96(6): 1598-1608. DOI: <https://www.doi.org/10.3382/ps/pew464>
- Lupiani B, Lee LF, Cui X, Gimeno I, Anderson A, Morgan RW, and Reddy SM (2004). Marek's disease virus-encoded Meq gene is involved in transformation of lymphocytes but is dispensable for replication. *Proceedings of the National Academy of Sciences*, 101(32): 11815-11820. DOI: <https://www.doi.org/10.1073/pnas.0404508101>
- Mescolini G, Lupini C, Davidson I, Massi P, Tosi G, and Catelli E (2020). Marek's disease viruses circulating in commercial poultry in Italy in the years 2015-2018 are closely related by their meq gene phylogeny. *Transbound Emergency Diseases*, 67(1): 98-107. DOI: <https://www.doi.org/10.1111/tbed.13327>
- Mohamed MA, El-Motelib TYA, Ibrahim AA, and El-Deen MES (2010). Contamination rate of avian leukosis viruses among commercial Marek's disease vaccines in Assiut, Egypt market using reverse transcriptase polymerase chain reaction. *Veterinary World*, 3(1): 8-12. Available at: <https://www.proquest.com/openview/31534814ce9facff84242167370de2de/1?cbi=746332&pq-origsite=gscholar>
- Murray HG and Thompson WF (1980). Rapid isolation of high molecular weight DNA. *Nucleic Acids Research*, 8(19): 4321-4325. DOI: <https://www.doi.org/10.1093/nar/8.19.4321>
- Nair V (2013). Latency and tumorigenesis in Marek's disease. *Avian Disease*, 57(2S1): 360-365. Available at: <https://www.doi.org/10.1637/10470-121712-Reg.1>
- Office international des epizooties (OIE) (2010). Terrestrial manual Marek's disease OIE manual for diagnostic techniques of livestock diseases. Office Internationals des Epizootics., Paris, France, pp. 496-506. Available at: [http://www.oie.int/fileadmin/Home/eng/Health\\_standards/them/2.03.13MAREKDIS.pdf](http://www.oie.int/fileadmin/Home/eng/Health_standards/them/2.03.13MAREKDIS.pdf)
- Office international des epizooties (OIE) (2016). Marek's disease in OIE terrestrial manual. Paris. Available at: [http://www.oie.int/fileadmin/Home/eng/Health\\_standards/them/2.03.13MAREKDIS.pdf](http://www.oie.int/fileadmin/Home/eng/Health_standards/them/2.03.13MAREKDIS.pdf)
- Padhi A and Parcells MS (2016). Positive selection drives rapid evolution of the meq oncogene of Marek's disease virus. *PLoS ONE*, 11(9): e0162180. Available at: <https://www.doi.org/10.1371/journal.pone.0162180>
- Payne L and Fadly A (1997). Leukosis: sarcoma group. In: B. Calnek, H. Barnes, C. Beard, L. McDougald, and Y. Saif (Editors), *Diseases of poultry*, 10<sup>th</sup> Edition. Iowa State University Press., Ames, IA, pp. 414-466. Available at: <https://himakahaunhas.wordpress.com/wp-content/uploads/2013/03/disease-of-poultry.pdf>
- Payne L and Venugopal K (2000). Neoplastic disease: Marek's disease, avian leukosis and reticuloendotheliosis. *Revue Scientifique et Technique*, 19(2): 544-564. DOI: <https://www.doi.org/10.20506/rst.19.2.1226>
- Rispens BH, van Vloten H, Mastenbroek N, Maas HJ, and Schat KA (1972). Control of Marek's disease in the Netherlands. II. Field trials on vaccination with an avirulent strain (CVI 988) of Marek's disease virus. *Avian Diseases*, 16(1): 126-138. Available at: <https://pubmed.ncbi.nlm.nih.gov/4337309/>
- Shamblin CE, Greene N, Arumugaswami V, Dienglewicz RL, and Parcells MS (2004). Comparative analysis of Marek's disease virus (MDV) glycoprotein-, lytic antigen pp38- and transformation antigen Meq-encoding genes: association of meq mutations with MDVs of high virulence. *Veterinary Microbiology*, 102(3-4): 147-167. DOI: <https://www.doi.org/10.1016/j.vetmic.2004.06.007>
- Silva RF, Fadly AM, and Taylor SP (2007). Development of a polymerase chain reaction to differentiate avian leukosis virus (ALV) subgroups: Detection of an ALV contaminant in commercial Marek's disease vaccines. *Avian Diseases*, 51: 663-667. DOI: [https://www.doi.org/10.1637/1933-5334\(2007\)2\[e6:DOAPCR\]2.0.CO;2](https://www.doi.org/10.1637/1933-5334(2007)2[e6:DOAPCR]2.0.CO;2)
- Smith EJ, Fadly AM, and Okazaki W (1979). An enzyme-linked immunosorbent assay for detecting avian leukosis-sarcoma viruses. *Avian Diseases*, 23(3): 698-707. DOI: <https://www.doi.org/10.2307/1589746>
- Soliman KN, El-Agroudi MA, Nadim S, and Abdel Halim MI (1954). The occurrence of the neural type of the avian leukosis complex in Egypt. *British Veterinary Journal*, 110(7): 271-274. DOI: [https://www.doi.org/10.1016/S0007-1935\(17\)50274-2](https://www.doi.org/10.1016/S0007-1935(17)50274-2)
- Soliman YA, Gamal MA, El-Nagar EM, Khattab MS, and Salem HM (2023). Detection of avian leukosis virus subgroup J in Egyptian ducks and chicken using molecular and histopathological approach and allocation of genetic mutations and recombination events in the envelope protein gene gp85. *Journal of Advanced Veterinary Research*, 13(2): 277-287. Available at: <https://advetresearch.com/index.php/AVR/article/view/1220>
- Tan L, Li J, Duan Y, Liu J, Zheng S, Liang X, Fang C, Zuo M, Tian G, and Yang Y (2024). Current knowledge on the

- epidemiology and prevention of Avian leukosis virus in China. *Poultry Science*, 103(9): 104009. DOI: <https://www.doi.org/10.1016/j.psj.2024.104009>
- Umar S, Munir MT, Ahsan U, Raza I, Chowdhury MR, Ahmed Z, and Shah MAA (2017). Immunosuppressive interactions of viral diseases in poultry. *Worlds Poultry Science Journal*, 73(1): 121-135. DOI: <https://www.doi.org/10.1017/S0043933916000829>
- Wang P, Lin L, Shi M, Li H, Gu Z, Li M, Gao Y, Teng H, Mo M, Wei T, and Wei P (2020). Vertical transmission of ALV from ALV-J positive parents caused severe immunosuppression and significantly reduced marek's disease vaccine efficacy in three-yellow chickens. *Veterinary Microbiology*, 244: 108683. DOI: <https://www.doi.org/10.1016/j.vetmic.2020.108683>
- Witter RL (1997). Increased virulence of Marek's disease virus field isolates. *Avian Disease*, 41(1): 149-163. Available at: <https://pubmed.ncbi.nlm.nih.gov/9087332/>
- Witter RL and Lee LF (1984). Polyvalent Marek's disease vaccines: Safety, efficacy and protective synergism in chickens with maternal antibodies. *Avian Pathology*, 13(1): 75-92. DOI: <https://www.doi.org/10.1080/03079458408418510>
- Witter RL and Schat KA (2003). Marek's disease. In: Y. M. Saif (Editor), *Diseases of poultry*. Blackwell Publishing., Iowa State University Press, pp. 407-465. Available at: <https://himakahaunhas.wordpress.com/wp-content/uploads/2013/03/disease-of-poultry.pdf>
- Witter RL, Calnek BW, Buscaglia C, Gimeno IM, and Schat KA (2005). Classification of Marek's disease viruses according to pathotype philosophy and methodology. *Avian Pathology*, 34(2): 75-90. DOI: <https://www.doi.org/10.1080/03079450500059255>
- Yehia N, El-Sayed HS, Omar SE, Erfan A, and Amer F (2021). Genetic evolution of Marek's disease virus in vaccinated poultry farms. *Veterinary World*, 14(5): 1342-1353. DOI: <https://www.doi.org/10.14202/vetworld.2021.1342-1353>
- Zhang YW, Su Q, Zhang ZH, Cui ZZ, Chang S, and Zhao P (2020). Molecular characteristics of the re-emerged avian leukosis virus in China, 2018-2019. *Transboundary and Emerging Diseases*, 67(3): 1141-1151 DOI: <https://www.doi.org/10.1111/tbed.13440>
- Zhuang X, Zou H, Shi H, Hongxia, S, Jianqiang Y, Ji M, Genghua W, and Aijian Q (2015). Outbreak of Marek's disease in a vaccinated broiler breeding flock during its peak egg-laying period in China. *BMC Veterinary Research*, 11: 157. DOI: <https://www.doi.org/10.1186/s12917-015-0493-7>

**Publisher's note:** [Scienceline Publication](#) Ltd. remains neutral with regard to jurisdictional claims in published maps and institutional affiliations.



**Open Access:** This article is licensed under a Creative Commons Attribution 4.0 International License, which permits use, sharing, adaptation, distribution and reproduction in any medium or format, as long as you give appropriate credit to the original author(s) and the source, provide a link to the Creative Commons licence, and indicate if changes were made. The images or other third party material in this article are included in the article's Creative Commons licence, unless indicated otherwise in a credit line to the material. If material is not included in the article's Creative Commons licence and your intended use is not permitted by statutory regulation or exceeds the permitted use, you will need to obtain permission directly from the copyright holder. To view a copy of this licence, visit <https://creativecommons.org/licenses/by/4.0/>.