








# The Effect of Nano-bentonite Supplementation on Reducing the Toxicity of Aflatoxin B1 in Kampung Unggul Balitbangan Chickens' Diet

Yunianta<sup>1\*</sup> , Ari Astuti<sup>1</sup> , Nanang Kusuma Mawardi<sup>1</sup> , Maria Theresia Darini<sup>2</sup> , Hermantoro Sastrohartono<sup>3</sup> , Khusnan<sup>4</sup> , and Mohammad Sofi'ul Anam<sup>5</sup> 

<sup>1</sup>Department of Agribusiness, Agriculture Program, Sarjanawiyata Tamansiswa University, Yogyakarta 55167, Indonesia

<sup>2</sup>Department of Agrotechnology, Agriculture Program, Sarjanawiyata Tamansiswa University, Yogyakarta 55167, Indonesia

<sup>3</sup>Department of Agricultural Engineering, Stiper Agricultural Institute, Yogyakarta 55282 Indonesia

<sup>4</sup>Animal Husbandry Academy Brahmputra, Yogyakarta 55162, Indonesia

<sup>5</sup>Department of Animal Nutrition and Feed Science, Faculty of Animal Science, Universitas Gadjah Mada, Yogyakarta 55281, Indonesia

\*Corresponding author's Email: [yunianta@ustjogja.ac.id](mailto:yunianta@ustjogja.ac.id)

Received: 05 April 2023

Accepted: 27 May 2023

## ABSTRACT

*Aspergillus flavus* and *Aspergillus parasiticus* are fungi that produce toxic secondary metabolites known as aflatoxins. These toxins can contaminate various food and feed products, including grains and nuts, before or after they are harvested. This contamination is most commonly found in tropical countries. Many studies have demonstrated that clay additions can reduce animal aflatoxin toxicity. The objective of this research was to study how the usage of Pacitan's local bentonite, located in East Java, Indonesia, could potentially decrease the harmful effects of aflatoxin B1 in native chicken species. The Masking Gel Calcification method was used to create bentonite nanoparticles at the Center for Ceramics in Bandung, West Java, Indonesia. The *in vivo* study was conducted at a native chicken farm in Bantul, Yogyakarta, Indonesia, with 1200 unsexed Kampung Unggul Balitbangan (KUB) chickens. Kampung Unggul Balitbangan chickens were divided into 4 treatments and 6 replications, each containing 50 chickens. The diets in the treatments were named as T0 (the control group in which chickens were fed basal diet, without aflatoxin B1), T1 (T0 + 200 µg/kg aflatoxin B1), T2 (T0 + 200 µg/kg aflatoxin B1 + 1 g/kg Factory Feed with standard factory absorbent), and T3 (T0 + 200 µg/kg aflatoxin B1 + 1 g/kg nano bentonite). *Aspergillus flavus* isolates from PAU Universitas Gadjah Mada were created using crude aflatoxin (FNC 2262). This study found a significant difference in KUB chicken performance, specifically in feed conversion ratio (FCR). Compared to T0, the findings indicated that T1 had the highest FCR value, followed by T2 and T3. It can be concluded that nanoparticle bentonite has a looser structure because of decreased packing density with the lowest FCR. Based on hematology analysis, it can suppress aflatoxin B1 toxicity in KUB chickens.

**Keywords:** Aflatoxin B1, *Aspergillus flavus*, Bentonite, Feed conversion ratio, Kampung Unggul Balitbangan chicken

## INTRODUCTION

Indonesia is among the world's most populous countries, so plant and animal nourishment production is critical. Chicken is one of the livestock that can be used as a source of animal protein. This domesticated animal is frequently raised by Indonesians and plays a significant role in supplying animal protein to the community. Local chicken is one of the dozens of strains of chicken that have the potential to be produced in Indonesia (Depison et al.,

2020). In 2019, there were 301,761,386 chickens in the local area, contributing 8.33%, or 292,329 tons, to the national production of poultry meat (Bakrie et al., 2021). The Kampung Unggul Balitbangan (KUB) chicken is a locally adapted type with significant genetic variability. Additionally, the Minister of Agriculture issued a decree on the release of KUB chicken, which was produced over six generations in West Java and DKI Jakarta from a combination of indigenous breeds (Masito et al., 2022). Following this development, the animal feed industry is a

rapidly growing poultry farming industry in Indonesia, with more than 34 animal feed manufacturers established by 2020. As a result, poultry feed producers (feed mills) will work hard to improve feed quality, which results in improved livestock production and efficiency.

Currently, a great effort is being made to avoid contaminations, such as aflatoxin, in feed (Mgbeahuruike et al., 2018). Aflatoxin, a secondary toxic metabolite of *Aspergillus* species, especially aflatoxigenic *Aspergillus flavus*, and *parasitica*, is harmful to poultry health and production (Motbaynor et al., 2021). Aflatoxicosis is a prominent issue associated with tropical poultry production (Mgbeahuruike et al., 2018). Considering the severe economic losses and health issues that aflatoxins pose, this toxin is a serious concern in poultry production and public health (El-Nabarawy et al., 2020). Aflatoxin contamination reduces feed quality and animal efficiency through poor nutrient conversion or problems such as reproductive abnormalities (Alahlah et al., 2021). Aflatoxicosis in poultry also results in listlessness, anorexia, a slower growth rate, poor feed utilization, lower egg production, and increased mortality (Oguz, 2011). Thus, it is critical to control these toxins' economic and health risks (Oguz, 2011).

Of the four forms of aflatoxin molecules, B1, B2, G1, and G2, aflatoxin B1 is the most common and significant toxigenic hazard (Kumar et al., 2017). In chickens, the small intestine rapidly absorbs aflatoxin B1 into the mesenteric venous blood (Noreddine, 2020). Aflatoxin B1 is the most potent carcinogen and can cause many systemic side effects and interfere with normal organ and tissue function, resulting in inhibition of growth, swelling, immune suppression, and an increased risk of liver cancer in humans and animals (Wogan et al., 2012). Aflatoxin B1 contamination can be found in corn, peanuts, and animal feed, with many exceeding the threshold (Nuryono et al., 2010; Yuniarta and Agus, 2013)

However, the aflatoxin risks can be avoided by using proper management measures to reduce mycotoxin contamination in agricultural products used as feed ingredients (during planting, harvesting, and storage, Kumar et al., 2021). Different approaches, whether physical, chemical, or biological, have been employed for elimination objectives. In the last decade, a binder or adsorbent that can effectively prevent aflatoxicosis was developed, and it is now used in industry to reduce the effects of aflatoxins (Nazarizadeh and Pourreza, 2019). The issue is that, in Indonesia, the binder is still entirely imported from developed countries. Commercially, clay's aluminosilicate has been utilized as a feed additive to

enhance the nutritional value of animal feed and as a binding agent for mycotoxins (Nadziakiewicz et al., 2019). Up to 2% of feed contains aluminum silicate as an anti-caking agent. The aluminosilicate group includes several members that fall under the phyllosilicate subclass, such as bentonite, montmorillonite, smectite, kaolinite, and illite (Kolossova and Stroka, 2011). On the other hand, zeolite and clinoptilolite are among the materials that do not belong to the phyllosilicate subclass (EFSA, 2009; Brezonik and Arnold, 2011).

According to the results of previous research, the administration of activated charcoal and bentonite clay produced better immunological and histopathological features than the control group (Ramandani, 2020). Much research has been done on this binder material, including by researchers with the mycotoxin team of Universitas Gadjah Mada, with natural bentonite obtained from Pacitan (East Java, Indonesia, Nuryono et al., 2012). Bentonite has been widely used as a feed additive to bind aflatoxins commercially, but feed mill industries in Indonesia generally use bentonite as an adsorbent imported from abroad. This study aimed to determine the effects of local bentonite from Pacitan, East Java, Indonesia, on the reduction of aflatoxin B1 toxicity in KUB chicken.

## MATERIALS AND METHODS

### Ethical approval

The current experiment was carried out at the poultry farm of PT. Sari Rosa Asih Feed Mill and CV Kurnia in Bantul, Yogyakarta, Indonesia. The Research Ethics Committee of the Faculty of Veterinary Medicine, Universitas Gadjah Mada, Yogyakarta, Indonesia, approved this study (0122/EC-FKH/Eks. /2022).

### Analysis of active and non-active nano bentonite

The first step to produce nano bentonite was collecting bentonite samples in Pacitan, East Java, Indonesia. Using the masking gel calcification method, the bentonite samples were then transported to the Center for Ceramics in Bandung, West Java, Indonesia, for Bentonite Nano Processing. The results were divided into two groups for activation after they were obtained. The two outcomes were then characterized using transmission electron microscopy (TEM, JEM-1400, Japan).

### Preparation of tested isolates

An inoculum of the fungus *Aspergillus flavus* from PAU Universitas Gadjah Mada in Yogyakarta, Indonesia,

was used to produce crude aflatoxin in the laboratory from corn, stored for 14 days with a moisture level of more than 18%. Aflatoxin crude was generated by the PAU-UGM Laboratory using the isolates FNCC 2262. The biological laboratory at Universitas Gadjah Mada, Yogyakarta, was used as the study's location. Corn with a moisture content ranging between 20-22% was stored for 14 days to produce naturally contaminated aflatoxin B1 corn as an additional measure. The Redascreen Aflatoxin kit (R-Biopharm AG, Germany) Enzyme-Linked Immunosorbent Assay (ELISA) and High-performance liquid chromatography (HPLC) were used to test the levels of aflatoxin B1 (Beyene et al., 2019).

### Experimental design

The presented study was carried out for eight weeks at the Commanditaire Vennootschap Kurnia in Bantul, Yogyakarta, Indonesia. The trial ran from August until October 2022. In the study, the chickens were initially provided with crumb feeding during the first week, and then gradually transitioned to the research feed in the following week to help them adjust to the new diet. Performance calculations for the chickens began in the second week. The chickens were provided with *ad libitum* water and feed, and their feeding was controlled three times a day. The feed was in the form of crumbles, which were processed by PT. Sari Rosa Asih's industry partner. The KUB chickens in this experiment were vaccinated with Newcastle Disease (ND) vaccine at 4 and 21 days old, and with the Gomboro vaccine at 16 days old. The Medivac La sota vaccine (PT. Medion Farma Jaya, Indonesia) was used for the ND vaccination, and the Gomboro vaccine (PT. Medion Ardhika Bhakti, Indonesia) was registered through drinking water. After the trial, when the chickens were 8 (eight) weeks old with an average weight of 277 g, the performance of KUB chickens was evaluated cumulatively. Four treatments and six replications were applied to a total of 1200 (600 males and 600 females) at the age of 450-old KUB chickens randomly assigned to 24 bamboo cages with electric heating. The average temperatures were 32.5°C during the day (12.00 p.m.) and 30.8°C in the afternoon (5.00 p.m.), respectively. For the first two weeks, heating lamps were utilized both during the day and at night. However, lamps were only utilized for lighting, with two 25-watt bulbs given in separate places from 6 p.m. until 5.00 a.m. for even lighting. The humidity was not particularly measured; however, it was consistently above 70% due to the rainy season during the study. The wire and wooden box cages utilized were 90 cm long, 60 cm wide, and 50

cm high, and each contained 25 chickens. Outside the cage walls were feeding and drinking stations constructed of plastic, with two of each provided in each cage. The four treatment groups are displayed in Table 1.

**Table 1.** Treatment grouping for Kampung Unggul Balitbangtan chickens aged eight weeks

Group	Treatment
T0	Control (basal diet, without aflatoxin B1)
T1	T0 + 200 µg/kg aflatoxin B1
T2	T0 + 200 µg/kg aflatoxin B1 + 1 g/kg Factory Feed with standard factory absorbent
T3	T0 + 200 µg/kg aflatoxin B1 + 1 g/kg nano bentonite

### Performance of the growth process and nutrient digestion

A basal feed with the composition of the ingredients shown in Table 2 was used for pretreatment in day-old chicks up until week 2 (NRC, 1994). The information that was logged weekly included body weight, feed intake, and feed conversion. Two chickens from each experimental group were chosen randomly and slaughtered at the experiment's conclusion for hematopathology and histopathology examinations.

### Hematology analysis

A 5 mL blood sample was collected from chickens by wing vein puncture within 2 minutes of removing the hen from its cage. The heparinized blood was stored on ice. Blood samples were centrifuged at x 700 for 15 minutes at 20°C (Cheng et al., 2001). Hemoglobin, leukocytes, Packed Cell Volume (PCV), Total Plasma Protein (TPP), and fibrinogen were analyzed. Blood smears were prepared by placing a drop of blood on a glass slide and fixing it with methanol.

### Histopathology analysis

After the trial was completed, two chickens from each treatment were subjected to ether anesthesia and subsequently dissected to extract the liver, spleen, and duodenum. The samples were preserved with 10% formalin, dehydrated, embedded in paraffin, and sectioned into slices that are 5 µm thick, ensuring the preservation of their integrity. These thin tissue slices were then mounted on glass slides and stained with Hematoxylin and eosin, which highlighted cellular structures and enabled observation of tissue morphology. Finally, the stained slides were examined under a microscope (Motic, China) to identify any abnormalities or histopathological changes with 40x magnification. The assessment and evaluation of

these changes are based on established criteria and scoring systems, which help to provide a standardized and

objective assessment of the tissues (Ross and Pawlina, 2010).

**Table 2.** The composition of the basal diet for a duration of 8 weeks

Feed ingredients	Kg	CP (%)	ME (Kcal/kg)	CFa (%)	CFi (%)	Ca (%)	P (%)	Met (%)	Lis (%)	Trp (%)
Corn	60	5.16	2.022	2.34	1.20	0.012	0.18	0.108	0.12	0.06
Soybeans	34	16.49	860.2	0.27	1.02	0.088	0.21	0.248	1.08	0.22
Tallow	2.5	-	175.25	2.50	-	-	-	-	-	-
Bisphosphonates	0.5	-	-	-	-	-	0.10	-	-	-
Lime	1	-	-	-	-	0.76	-	-	-	-
Multivitamins	0.35	-	-	-	-	-	-	-	-	-
Fine	1.5	-	-	-	-	-	-	-	-	-
Total	100	21.65	3057.5	5.11	2.22	0.94	0.49	0.356	1.20	0.28

Kg: Kilogram; CP: Crude protein; ME: Metabolizable energy; CFa: Crude fat; CFi: Crude fiber; Ca: Calcium; P: Phosphorus; Met: Methionine; Lis: Lysine; and Trp: Tryptophan (Source: NRC, 1994).

**Statistical analysis**

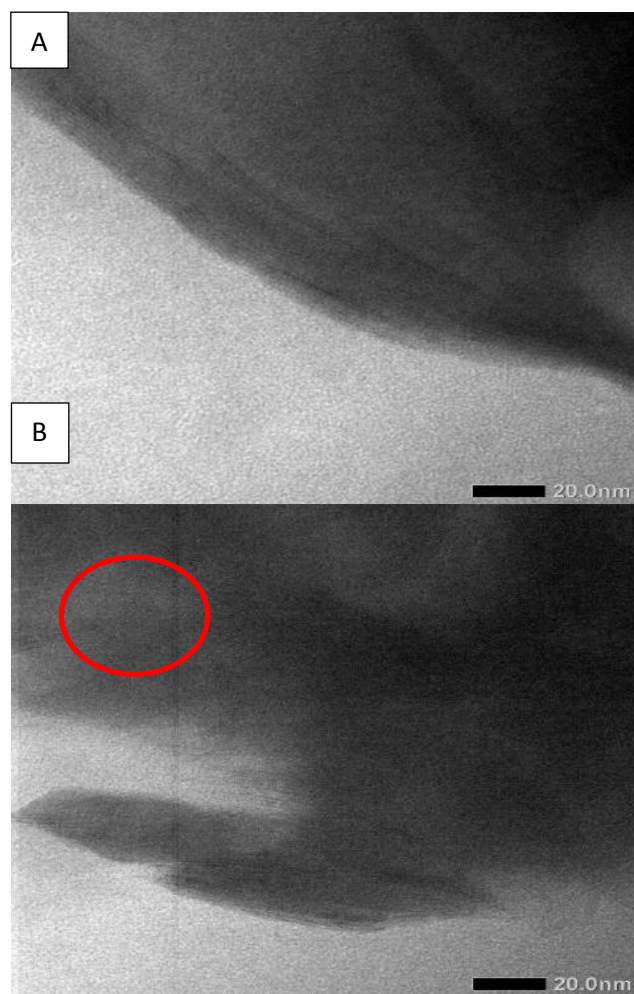
Body weight, feed consumption, and feed conversion were all tracked every week. Data obtained were analyzed using SPSS software (version 22). In a Completely randomized design (CRD), the ANOVA was used, and Duncan’s Multiple Range Test was followed to find the significant level. The chosen level of significance for all comparisons was  $p < 0.05$ .

**RESULT AND DISCUSSION**

In the previous investigations, bentonite was also utilized as an aflatoxin absorbent; however, the highest aflatoxin absorption was only 78% (Nuryono et al., 2012). This low absorption could be because the particles used in this study were micron-sized. In the present study, the morphology of bentonite-A and B was investigated using a transmission electron microscope. The findings are shown in Figure 1. According to Gong et al. (2016), bentonite-A and B micrographs show a structure made up of thin layers.

Figure 1 A depicts the inter-silicate layer on bentonite-A, enabling observation of the monolayer silicate layers. The dark shade, consistent throughout the sample, reveals the well-defined structure of the inter-silicate layer in bentonite-A. This structure's clarity allows for a comprehensive view of the bentonite-A layers, allowing for an in-depth examination of their properties. Figure 1 B, on the other hand, shows that the shade of the bentonite-B sample is less dark in some areas, especially in the red circle, suggesting a looser structure. This could be due to the inter-silicate layers' decreased packing density, which can cause variations in the degree of coloration. Other variables, such as differences in mineral

composition or processing techniques, could also account for the looser structure of the bentonite-B sample.



**Figure 1.** The morphological characteristics of natural (A) and activated (B) bentonite under transmission electron microscopy at a 20 nm spatial resolution

**Table 3.** HPLC and ELISA analysis of feed for Kampung Unggul Balitbangtan chickens aged 8 weeks

Treatment	HPLC (ppb)	ELISA (ppb)
T0	-	13.0
T1	236.0	208.0
T2	192.0	224.0
T3	178.0	218.0

HPLC: High-performance liquid chromatography; ELISA: Enzyme-Linked Immunosorbent Assay; T0: Control (basal diet, without aflatoxin B1); T1: T0 plus 200 µg/kg aflatoxin B1; T2: T0 plus 200 µg/kg aflatoxin B1 plus 1 g/kg factory feed with standard factory absorbent; T3: T0 plus 200 µg/kg aflatoxin B1 plus 1 g/kg nano bentonite

An analysis was carried out using HPLC and ELISA to determine the degree of aflatoxin B1 contamination in the animal feed utilized in this experiment. The fundamental goal of HPLC is to identify, quantify, and analyze the concentrations of active components in a sample; meanwhile, the basis of ELISA is the highly-sensitive and specific interactions between antigens and antibodies. Table 3 indicates that the highest level of contamination was observed in T1 during HPLC analysis, where the base diet was contaminated with 200 µg/kg of aflatoxin B1. However, during ELISA analysis, the highest contamination was detected in T2, where the base diet was contaminated with 200 µg/kg of aflatoxin B1, and 1 g/kg of standard factory absorbent was added.

The T3 treatment with a basal diet combined with 200 µg/kg aflatoxin B1 and 1 g/kg nano bentonite had the lowest value on HPLC analysis in the aflatoxin B1-contaminated treatment. Bentonite, a type of clay, is abundant in silica and aluminum minerals that contain OH groups. These OH groups can bind with the hydrogen substrate of aflatoxins, causing them to transform into H<sub>2</sub>O and be eliminated from the chicken's body via the urinary system. The ability of bentonite to absorb toxins in the gastrointestinal tract is a widely recognized mechanism. It works by slowing down nutrient movement in the intestine, which results in slower digestion and increased feed digestibility. It is possible to improve the availability of lipase, phospholipase, and carbohydrase by employing bentonite, which is rich in silicon and aluminum. It is because bentonite enhances the binding of digestive enzymes or co-factors (Moosavi, 2017).

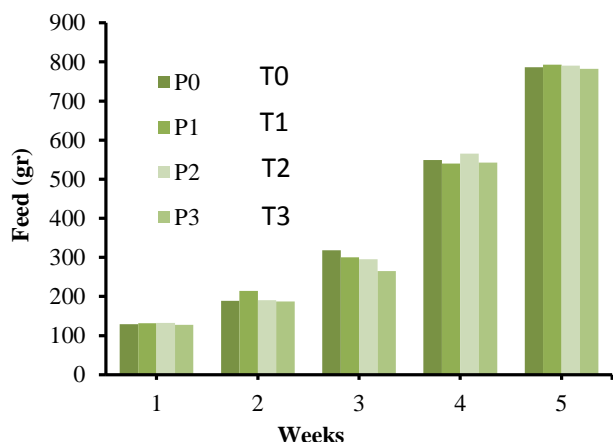
The results of research performance that considered feed intake, body weight, and feed conversion ratio are shown in Table 4. The feed consumption in this study ranged from 786.82 to 792.79 g (Figure 2). The statistical analysis of each treatment did not indicate any significant differences in the outcomes ( $p < 0.05$ ). It is likely because the treatment feed was formulated using identical ingredients and had comparable levels of protein and energy, with a crude protein content of 19% and a metabolic energy level of 2,800 kcal/kg. As a result, it was possible to achieve similar feed consumption across all treatments without any notable disparities. According to research on feed consumption in KUB chickens of that age in different Indonesian locations, it ranged from 727 to 776 g, 600 to 700 g, and 450 to 500 g, and in the meantime, it reached 803 to 870 g (Sinurat, 2017; Yuniarta et al., 2021). It demonstrates that feed consumption throughout the trial was within the usual range for commercial feed that is not contaminated with aflatoxin and those that have binders added to it.

Table 4 shows the subjects' body weight during the investigation. T0 had the highest weight (538.77 g), while T1 had the lowest (424.27 g). According to the statistical analysis, there was a substantial weight loss in the aflatoxin-contaminated meal for T0 compared to T1 ( $p < 0.05$ ). Aflatoxin-free diet did not significantly differ from feed containing a commercial binder and nano bentonite, so commercial binder and nano binder may prevent weight loss brought on by aflatoxin contamination ( $p < 0.05$ ). Figure 3 illustrates that the weight of KUB chickens in the T0 treatment group consistently increased over the course of the study, resulting in overall stable weight, while the T1 treatment group exhibited a delay in weight gain during the final week of the experiment. In the first and second weeks of the study, there was still no significant difference between the T1 treatment group and other treatments in terms of feed consumption ( $p < 0.05$ ). This is due to aflatoxin not being utilized at T0 and its mixing without a binder at T1. The results show how aflatoxin contamination in the chicken's feed impacted the growth of muscle mass. The body weight of chickens can vary significantly, as evidenced by previous research (Kurniasih and Prakoso, 2019).

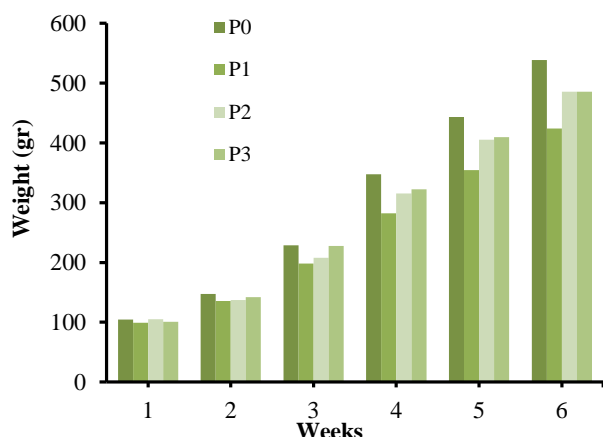
**Table 4.** Performance of Kampung Unggul Balitbangtan chickens aged 8 weeks

Mean ± SD Treatment	Body weight (g)	Feed consumption (g)	Feed/bodyweight ratio
T0	538.77 <sup>a</sup> ± 28.57	786.82 <sup>a</sup> ± 13.14	1.78 <sup>c</sup> ± 0.11
T1	424.27 <sup>b</sup> ± 31.24	792.79 <sup>a</sup> ± 45.38	2.24 <sup>a</sup> ± 0.23 <sup>c</sup>
T2	485.78 <sup>a</sup> ± 22.42 <sup>a</sup>	790.20 <sup>a</sup> ± 16.99	1.95 <sup>b</sup> ± 0.16 <sup>b</sup>
T3	485.65 <sup>a</sup> ± 23.04 <sup>a</sup>	782.21 <sup>a</sup> ± 15.80	1.92 <sup>b</sup> ± 0.13 <sup>c</sup>

<sup>a-c</sup> Means within each column with different superscripts are statistically different  $p < 0.05$ . SD: Standard Deviation; T0: Control (basal diet, without aflatoxin B1); T1: T0 plus 200 µg/kg aflatoxin B1; T2: T0 plus 200 µg/kg aflatoxin B1 plus 1 g/kg factory feed with standard factory absorbent; T3: T0 plus 200 µg/kg aflatoxin B1 plus 1 g/kg nano bentonite



**Figure 2.** Feed consumption of Kampung Unggul Balitbangtan chickens for five weeks. T0: Control (basal diet, without aflatoxin B1), T1: T0 plus 200 µg/kg aflatoxin B1, T2: T0 plus 200 µg/kg aflatoxin B1 plus 1 g/kg factory feed with standard factory absorbent, T3: T0 plus 200 µg/kg aflatoxin B1 plus 1 g/kg nano bentonite.

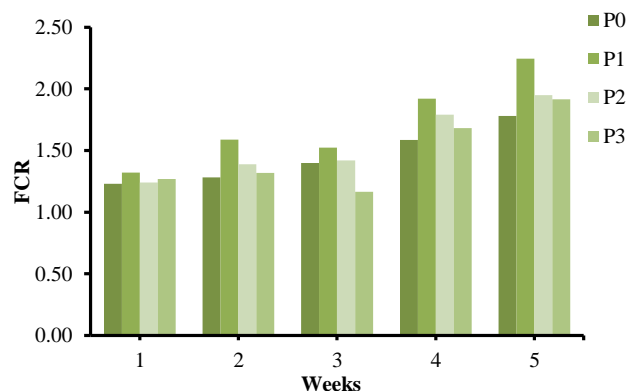


**Figure 3.** Weight gain of Kampung Unggul Balitbangtan chickens for 6 weeks. T0: Control (basal diet, without aflatoxin B1), T1: T0 plus 200 µg/kg aflatoxin B1, T2: T0 plus 200 µg/kg aflatoxin B1 plus 1 g/kg factory feed with standard factory absorbent, T3: T0 plus 200 µg/kg aflatoxin B1 plus 1 g/kg nano bentonite.

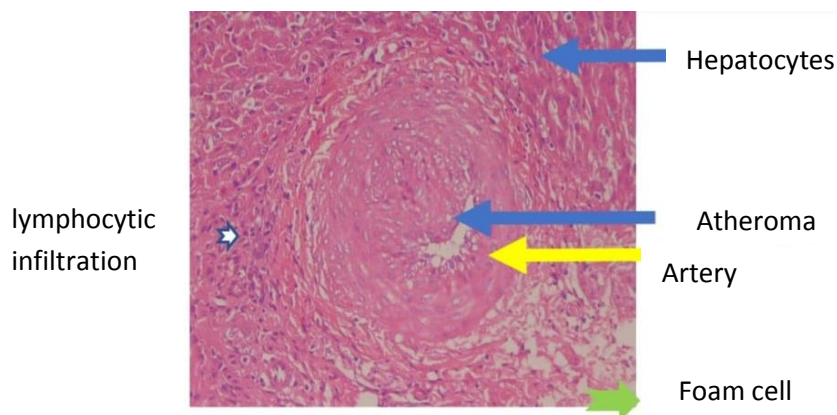
According to Table 4, group T1 demonstrated a significantly higher Feed Conversion Ratio (FCR) compared to the other groups ( $p < 0.05$ ). This result confirmed that aflatoxin had affected the chicken's metabolism by disrupting the function of the intestines and liver (Zuidhof et al., 2014). Additionally, Figure 4 shows that among the treatment group infected with aflatoxin, T2 had the highest FCR, and T0 had the lowest. It is because the weight of the KUB Chicken organs engaged negatively

impacts aflatoxin due to cellular abnormalities (Kurniasih and Prakoso, 2019). In this research, the aflatoxin-contaminated feed had a higher feed conversion ratio (FCR) than the control feed that was not contaminated with aflatoxin. Similarly, a hepatological examination of the liver revealed liver damage in the contaminated feed group, especially in the adsorbent-free group (T1). It suggests that aflatoxin-contaminated grain increases FCR. This negative impact, however, can be mitigated by using nano bentonite adsorbents or commercial adsorbents in the feed. This result is consistent with Yunianta and Agus (2013) research, which found that broiler chickens fed with aflatoxin-contaminated feed had liver damage, which can disrupt metabolism and reduce productivity.

The atheroma was observed in the tunica media, which is attributed to the damaging effects of aflatoxin on the endothelium. The intima also included foam cells. At the cellular level, increased vacuolation of aflatoxin-exposed hepatocytes allows for the accumulation of high levels of lipids, which is why foam cells form. Lymphocyte infiltration occurs when lymphocytes invade the hepatic portal vein and form clumps or follicles. The increased formation of globules of triglycerides and other lipid metabolites within the cytoplasm is known as hepatocellular fatty vacuolation (hepatocyte degeneration), which results in microscopic holes or blank areas in the liver. Necrosis will result from hepatocytes that have too much fat in them. Table 5 displays the impact of each treatment on the liver, spleen, and lungs.



**Figure 4.** Feed conversion ratio chart of Kampung Unggul Balitbangtan chickens for five weeks. T0: Control (basal diet, without aflatoxin B1), T1: T0 plus 200 µg/kg aflatoxin B1, T2: T0 plus 200 µg/kg aflatoxin B1 plus 1 g/kg factory feed with standard factory absorbent, T3: T0 plus 200 µg/kg aflatoxin B1 plus 1 g/kg nano bentonite.



**Figure 5.** The hepatic tissue of Kampung Unggul Balitbangtan chicken received aflatoxin B1 and factory feed with standard factory absorbent. The triassic zone, Hematoxylin and eosin, 40x

**Table 5.** Effects of several treatments on the liver, spleen, and lung of Kampung Unggul Balitbangtan chicken for 8 weeks

Treatment	Liver	Spleen	Lung
T0	No pathological changes Mild lipidosis scale 2	There were no pathological changes	There were no pathological changes
T1	Multifocal necrosis Severe lipidosis scale 4 Mild lymphocytic infiltration	25% necrosis Lymphocyte	25% had pneumonia
T2	Bridging necrosis Severe lipidosis scale 4 Mild lymphocytic infiltration	25% necrosis Lymphocyte	25% had pneumonia
T3	No necrosis Mild lipidosis on a scale of 1 Multifocal and 50% parenchymal infiltration	25% necrosis Lymphocyte	25% had pneumonia

T0: Control (basal diet, without aflatoxin B1); T1: T0 plus 200 µg/kg aflatoxin B1; T2: T0 plus 200 µg/kg aflatoxin B1 plus 1 g/kg factory feed with standard factory absorbent; T3: T0 plus 200 µg/kg aflatoxin B1 plus 1 g/kg nano bentonite.

**Table 6.** Blood parameters of old Kampung Unggul Balitbangtan chickens aged 8 weeks after several treatments

Treatment	Erythrocyte (10 <sup>6</sup> /µL)	PCV (g/dL)	TPP (%)	Fibrinogen (cells/µL)	Leukocytes (cells/µL)
T0	3.47	27.50	4.47	0.60	10375
T1	0.99	23.00	4.30	0.90	19125
T2	1.16	27.25	4.80	0.45	16866
T3	1.36	31.25	4.25	0.30	17975

PCV: Packed cell volume; TPP: Total plasma protein; T0: Control (basal diet, without aflatoxin B1); T1: T0 plus 200 µg/kg aflatoxin B1; T2: T0 plus 200 µg/kg aflatoxin B1 plus 1 g/kg factory feed with standard factory absorbent; T3: T0 plus 200 µg/kg aflatoxin B1 plus 1 g/kg nano bentonite

Table 6 contains data on collected and analyzed blood samples of KUB chickens. As shown in Table 6, Aflatoxin B1 infection resulted in a decrease in erythrocyte production when compared to T0 (control,  $p < 0.05$ ). Among the three groups that received Aflatoxin B1, group T3 had the highest erythrocyte count. Aplastic anemia is defined by low erythrocyte counts (Hsi-Tang et al., 1975). Mild anemia is usually present when the packed cell volume (PCV) of the blood being examined is low

(Nwogor et al., 2015). The treatment of the T3 group indicates that this group had no anemia. This study's analysis of the total plasma protein (TPP) test did not show any significant differences between the different treatment groups ( $p < 0.05$ ). It is possible due to the liver's minor but non-fatal damage, which enables near-normal albumin production. When activated by infection, the amount of fibrinogen in the blood increases (Roy et al., 2014). According to the data in Table 6, the fibrinogen in

the T3 group's treatment had the lowest value. If the blood leukocyte count is high, it is likely that the leukocytes are actively fighting an internal infection or that the organism is experiencing a stressful period (James et al., 2019). Even though the T3 group's value in the leukocytes test is not the lowest, it is not far from it. It can be inferred that the nano-bentonite binder effectively bound the toxin, Aflatoxin B1, in the feed mill.

## CONCLUSION

Based on the findings of this research, it is achievable to determine that using nano bentonite as an adsorbent in Kampung Unggul Balitbangtan chicken diets contaminated with aflatoxin can significantly reduce its toxicity. According to the hematological analysis, the binder was more effective in group T3 where they had the highest erythrocyte count and the lowest fibrinogen, resulting in a reduced feed conversion ratio value. To completely comprehend the efficacy of nano bentonite as an adsorbent for aflatoxin-contaminated Kampung Unggul Balitbangtan chicken diets, more research is recommended until the production stage of local chickens is reached.

## DECLARATION

### Acknowledgments

The authors express their profound gratitude to the Ministry of Education, Culture, Research, and Technology for funding this research through Matching Fund Kedaireka (Business Cooperation and Creative Creations). The sincere thanks also go to PT Sari Rosa Asih and Balai Besar Keramik as colleagues on this experiment.

### Authors' contributions

Yunianta, Ari Astuti, and Hermantoro Sastrohartono conducted the experiment; Nanang Kusuma Mawardi, Maria Theresia Darini, Khusnan, and Mohammad Sofi'ul Anam conducted the analysis and data calculations; and Yunianta, Ari Astuti, Nanang Kusuma Mawardi, and Maria Theresia Darini wrote and revised the manuscript. All authors agreed to the final version of this manuscript.

### Competing interests

The author states that this manuscript has no personal or other conflicts of interest.

### Ethical consideration

All authors have reviewed all essential ethical issues.

## Availability of data and materials

The authors confirm that the data supporting the study's results are accessible upon reasonable request from the corresponding author.

## REFERENCES

- Alahlah N, El Maadoudi M, Bouchriti N, Triqui R, Stitou M, Hafid NH, and El Ouahabi O (2021). Occurrence of aflatoxin B1 in animal feed collected from the Northeastern area of Morocco. *World Veterinary Journal*, 11(4): 587-593. DOI: <https://www.doi.org/10.54203/scil.2021.wvj74>
- Bakrie B, Rohaeni ES, Yusriani Y, and Tirajoh S (2021). The development of a newly formed superior local chicken in Indonesia – A review. *Journal of Hunan University Natural Sciences*, 48(9): 25-34. Available at: <http://jonuns.com/index.php/journal/article/view/740>
- Beyene AM, Du X, Schrunk DE, Ensley S, and Rumblei WK (2019). High-performance liquid chromatography and enzyme-linked immunosorbent assay techniques for detection and quantification of aflatoxin B1 in feed samples: A comparative study. *BMC Research Notes*, 12: 492. DOI: <https://www.doi.org/10.1186/s13104-019-4538-z>
- Brezonik P and Arnold W (2011). *Water chemistry: An introduction to the chemistry of natural and engineered aquatic systems*. Oxford University Press., USA. Available at: [https://www.books.google.co.id/books/about/Water\\_Chemistry.html?id=v4yd3WTpriEC&redir\\_esc=y](https://www.books.google.co.id/books/about/Water_Chemistry.html?id=v4yd3WTpriEC&redir_esc=y)
- Cheng HW, Eicher SD, Chen Y, Singleton P, and Muir WM (2001). Effect of genetic selection for group productivity and longevity on immunological and hematological parameters of chickens. *Poultry Science*, 80(8): 1079-1086. DOI : <https://www.doi.org/10.1093/ps/80.8.1079>
- Depison, Puteri NI, and Gushairiyanto (2020). Growth patterns, body weight, and morphometric KUB chicken, Sentul chicken, and Arab chicken. *Buletin Peternakan*, 44(3): 67-72. DOI: <https://www.doi.org/10.21059/buletinpeternak.v44i3.57016>
- El-Nabarawy AM, Ismael E, Shaaban KhA, El Basuni SS, Batikh MM, and Shakal M (2020). Mycotoxin contamination levels in broiler feeds and aflatoxin residues in broiler tissues. *Journal of World's Poultry Research*, 10(2S): 133-144. Available at: [https://www.jwpr.science-line.com/attachments/article/55/JWPR%2010\(2S\)%20133-144.%202020.pdf](https://www.jwpr.science-line.com/attachments/article/55/JWPR%2010(2S)%20133-144.%202020.pdf)
- European food safety authority (EFSA) (2009). Risk Assessment for Birds and Mammals. *The EFSA Journal*, 7(12): 1438. DOI: <https://www.doi.org/10.2903/j.efsa.2009.1438>
- Gong Z, Liao L, Lv G, and Wang X (2016). A simple method for physical purification of bentonite. *Applied Clay Science*, 119(2): 294-300. DOI: <https://www.doi.org/10.1016/j.clay.2015.10.031>
- Hsi-Tang T, Cook FW, Wyatt RD, and Hamilton PB (1975). The anemia caused by aflatoxin. *Poultry Science*, 54(6): 1962-1969. DOI: <https://www.doi.org/10.3382/ps.0541962>
- James G, Danwake JG, Adekojo SA, Zarma A, and Zakari M (2019). Effect of different bedding materials on the hematological and serum biochemical parameters of broiler chickens. *Journal of World's Poultry Research*, 9(2): 55-58. Available at: [https://www.jwpr.science-line.com/attachments/article/49/J%20World%20Poult%20Res%209\(2\)%2050-58.%202019.pdf](https://www.jwpr.science-line.com/attachments/article/49/J%20World%20Poult%20Res%209(2)%2050-58.%202019.pdf)
- Kolosova A and Stroka J (2011). Substances for reduction of the contamination of feed by mycotoxins: a review. *World Mycotoxin Journal*, 4: 225-256. DOI: <https://www.doi.org/10.3920/WMJ2011.1288>

- Kumar A, Pathak H, Bhadauria, S, and Sudan J (2021). Aflatoxin contamination in food crops: causes, detection, and management: A review. *Food Production, Processing and Nutrition*, 3: 17. DOI: <https://www.doi.org/10.1186/s43014-021-00064-y>
- Kumar P, Mahato DK, Kamle M, Mohanta, and Kang SG (2017). Aflatoxins: A global concern for food safety, human health and their management. *Frontiers in Microbiology*, 7: 2170. DOI: <https://www.doi.org/10.3389/fmicb.2016.02170>
- Kurniasih and Prakoso YA (2019). Recent update: Effects of aflatoxin in broiler chickens. *Journal of World's Poultry Research*, 9(2): 68-77. Available at: [https://www.jwpr.science-line.com/attachments/article/49/J%20World%20Poult%20Res%209\(2\)%2068-77.%202019.pdf](https://www.jwpr.science-line.com/attachments/article/49/J%20World%20Poult%20Res%209(2)%2068-77.%202019.pdf)
- Masito M, Putra ARS, and Andarwati S (2022). The effect of Kampung Unggul Balintangtan (KUB) chicken innovation characteristics toward the development of farmers' perceptions in South Sumatra. *IOP Conference Series: Earth and Environmental Science*. 1001: 012027. DOI: <https://www.doi.org/10.1088/1755-1315/1001/1/012027>
- Mgbeahuruie AC, Ejioffor TE, Christian OC, Shoyinka VC, Karlsson M, and Nordkvist E (2018). Detoxification of aflatoxin-contaminated poultry feeds by 3 adsorbents, bentonite, activated charcoal, and Fuller's earth. *Journal of Applied Poultry Research*, 27(4): 461-471. DOI: <http://www.doi.org/10.3382/japr/pfy054>
- Moosavi M (2017). Bentonite clay as a natural remedy: A brief review. *Iran Journal of Public Health*, 46(9): 1176-1183. Available at : <https://www.ncbi.nlm.nih.gov/pmc/articles/PMC5632318/>
- Motbaynor A, Kassaye D, Keffale M, and Wasihun P (2021). The magnitude of aflatoxigenic aspergillus species, level of aflatoxin B1, and associated factors in stored feed at poultry farms in Dire Dawa, Ethiopia. *Veterinary Medicine International*, 2021: 6638083. DOI: <https://www.doi.org/10.1155/2021/6638083>
- Nadziakiewicz M, Kehoe S, and Micek P (2019). Physico-chemical properties of clay minerals and their use as a health promoting feed additive. *Animals*, 9(10): 714. DOI: <https://www.doi.org/10.3390/ani9100714>
- National research council (NRC) (1994). *Nutrient requirements of poultry*, 9th Revised Edition. The National Academies Press., Washington, DC. DOI: <https://www.doi.org/10.17226/2114>
- Nazarizadeh H and Pourreza J (2019). Evaluation of three mycotoxin binders to prevent the adverse effects of aflatoxin B1 in growing broilers. *Journal Of Applied Animal Research*, 47(1): 135-139. DOI: <https://www.doi.org/10.1080/09712119.2019.1584106>
- Noreddine B (2020). Chronic and acute toxicities of aflatoxins: Mechanisms of action. *International Journal of Environmental Research and Public Health*, 17(2): 423. DOI: <https://www.doi.org/10.3390/ijerph17020423>
- Nuryono, Agus A, Wedastri S, Maryudani YMS, Pranowo D, Yuniarta, and Razzazi-Fazeli E (2012). Reduction of aflatoxin B1 contamination in corn with natural bentonite and zeolite. *Indonesian Journal of Chemistry*, 12(3): 279-286. Available at : <https://www.jurnal.ugm.ac.id/ijc/article/view/21343>
- Nuryono, Wedastri S, Yuniarta, Maryudhani YB, and Agus A (2010). Production of crude Aflatoxin B1 using different isolates and substrates. 32<sup>nd</sup> Mycotoxin Workshop, Lyngby, Denmark, Poster 86. Available at: <https://www.pdfslide.net/documents/32nd-mycotoxin-workshop-14th-16th-june-2010-lyngby-june-15th17th.html?page=1>
- Nwogor UA, Uche OA, ifeyinwa EC, and Emmanuel AC (2015). Effect of locally produced blood meal on growth performance and packed cell volume of broiler chicks. *American Journal of Agriculture and Forestry*, 3(3): 105-108. DOI: <https://www.doi.org/10.11648/j.ajaf.20150303.17>
- Oguz H (2011). A review from experimental trials on detoxification of aflatoxin in poultry feed. *Eurasian Journal of Veterinary Science*, 27(1): 1-12. Available at: [https://eurasianjvetsci.org/pdf/pdf\\_EJVS\\_540.pdf](https://eurasianjvetsci.org/pdf/pdf_EJVS_540.pdf)
- Ramandani D, Ummami R, Hidayah N, Dalimunthe N, Indarjulianto S, Yanuartono, and Nururrozi A (2020). Effects of bentonite clay and activated charcoal as aflatoxin binders based on the immunological and histopathological changes in Kampung chicken. *Journal of Tropical Animal and Veterinary Science*, 10(1): 63-69. DOI: <https://www.doi.org/10.46549/jipvet.v10i1.94>
- Ross MH and Pawlina W (2010). *Histology: A text and atlas: With correlated cell and molecular biology*, 6<sup>th</sup> Edition. Lippincott Williams & Wilkins., United States. Available at: <https://www.zlibrary.to/pdfs/histology-a-text-and-atlas-with-correlated-cell-and-molecular-biology-6th-edition>
- Roy K, Bertelsen MF, Pors SE, Johansen KW, Kristensen AT, Kjelgaard-Hansen M, Andreasen EB, Christensen JP, Biswas PK, and Bojesen AM (2014). Inflammation-induced hemostatic response in layer chickens infected with *Streptococcus equi* subsp. *zooepidemicus* as evaluated by fibrinogen, prothrombin time, and thromboelastography. *Avian Pathology*, 43(4): 364-370. DOI: <https://www.doi.org/10.1080/03079457.2014.938608>
- Sinurat AP, Hidayat C, Haryati T, Wardhani T, and Satika T (2017). The effect of BS4 enzyme supplementation on the performance of local chicken-KUB during growing period. *Prosiding Seminar Nasional Teknologi Peternakan dan Veteriner*. pp. 402-408. Available at: <http://www.repository.pertanian.go.id:8080/server/api/core/bitstreams/ffe6383e-aa1b-4a9d-9cb1-70ccbc0ef2f7/content>
- Wogan GN, Kensler TW, and Groopman JD (2012). Present and future directions of translational research on aflatoxin and hepatocellular carcinoma: A review. *Food Additives Contaminants: Part A*, 29(2): 249-257. DOI: <http://www.doi.org/10.1080/19440049.2011.563370>
- Yuniarta and Agus A (2013). Reduction of level contaminant and toxicity of aflatoxin B1 in corn and its utilized in broiler feed. *Disertation Universitas Gadjah Mada, Yogyakarta*. Available at: [http://www.etd.repository.ugm.ac.id/home/detail\\_pencarian/63542](http://www.etd.repository.ugm.ac.id/home/detail_pencarian/63542)
- Yuniarta, Kusmanto D, and Agustin C (2021). Fermentasi bekatul sebagai pakan alternatif ayam kampung di yayasan seraphine sleman yogyakarta, prosiding. *Seminar Nasional Pengabdian kepada Masyarakat*, 6(1), 155-159. DOI: <https://www.doi.org/10.21460/sendimasvi2021.v6i1.40>
- Zuidhof MJ, Schneider BL, Carney VL, Korver DR, and Robinson FE (2014). Growth, efficiency, and yield of commercial broilers from 1957, 1978, and 2005. *Poultry Science*, 93(12): 2970-2982. DOI: <https://www.doi.org/10.3382/ps.2014-04291>