

The Effect of *In Ovo* Exposition to Ethanol Upon Osteogenesis of the Chicken Embryo

Hadjira Boussouar^{1*}, Tarek Khenenou², Omar Bennoune³ and Amine Berghiche⁴

¹ Department of Veterinary Sciences, Institute of Veterinary Sciences and Agronomic Sciences, Batna University 1, Batna 05000, Algeria

² Laboratory of Animal Productions, Biotechnology and Health, Institute of Agronomic and Veterinary Sciences, Mohamed Cherif Messaadia University, Souk Ahras, Algeria

³ ESPA Laboratory, Department of Veterinary Sciences, Institute of Veterinary Science and Agricultural Sciences, Batna University 1, Batna 05000, Algeria

⁴ Laboratory of Science and Technique of Living, Institute of Agronomic and Veterinary Sciences, Mohamed Cherrif Messaadia University, Souk Ahras, Algeria

*Corresponding author's Email: hadjiraboussouar05@gmail.com; ORCID: [0000-0003-3404-7838](https://orcid.org/0000-0003-3404-7838)

Received: 17 Apr. 2019

Accepted: 17 May 2019

ABSTRACT

Excessive alcohol consumption by a pregnant woman may delay foetal development and may cause malformations. In this study, the model of the chicken embryo to demonstrate the teratogenic effect of ethanol (33%) on the chicken osteogenesis on the 10th day of embryonic development have been used. 49 fertilized eggs were used in present investigation. Hence, different doses of ethanol were injected into the chicken embryos at 33% (20, 40, 80 µl) in the air space at gastrulation and, on the other hand, an equivalent amount of the mentioned doses of distilled water were injected into the control-group eggs which was done once in every two days in order to maintain a high concentration in the blood. Experiments were repeatedly and independently carried out for three times. The eggs were incubated in a humid incubator at the temperature of 37.7 °C and at 60-65% of humidity. On the 10th day of incubation, the embryos were taken out and fixed in formalin at 10%. After that, the eggs were sectioned at 5µm of thickness with a Leica micrtome and, then, stained with the Hematoxylin and eosin. Histological examination has revealed that the exposition of chicken embryos to ethanol (33%) delays the skeletal development in a dose-dependent manner by reducing the length of the cartilaginous proliferation zone and hypertrophic zone during the bone formation period. Furthermore, under the effect of ethanol, the cell proliferation activities were repressed. In conclusion, present results indicated that using ethanol to treat chicken embryos at early stages caused considerable malformations and a decreased in the embryo survival rate. The exposition to alcohol affects the chicken osteogenesis in a dose-dependent manner.

Key words: Chicken embryo, Ethanol, Malformations, Osteogenesis, Teratogenic effect

INTRODUCTION

Alcohol is considered as the most common teratogen in the occidental world. Its consumption during pregnancy may pave the way to a disease called Foetal Alcohol Syndrome or, under its softest form, Foetal Alcohol Effects (Chaudhuri, 2004). This is very worrying, if anyone consider the increase of alcohol consumption by women in the world (Chaudhuri, 2004). Despite the fact that the rate of alcohol consumption has been relatively steady through the last 30 years, the rate of women who consumed alcohol increased by 12.4% in 1991 and by 16.3% in 1995. Meanwhile, the number of newborns suffering from the Foetal Alcohol Syndrome (FAS) quadrupled between 1979 and 1993 with an incidence rate

of 6.7 per 10 000 births in 1993 (Miller et al., 2001). The negative clinical results of alcohol consumption during pregnancy may include an increased neonatal mortality, head and facial anomalies, a microcephaly, body organs disorder (Bupp Becker and Shibley, 1998). Including growth delay, muscle and skeletal anomalies and intellectual and behavioural disability (McGill et al., 2009). Various animal models have been used by researchers in order to study the factors and effects of various alcohol-related diseases. Such models have helped researchers to explore the mechanisms by which short-term and long-term consumption may interfere with the normal embryo-development processes (Kamran et al., 2011).

The chicken embryo (*Gallus gallus*) is an extremely useful model for the development biology, experimental embryology and teratology (Drake et al., 2006). Accurate and full descriptions of the development of chicks are widely available (Drake et al., 2006). Using chicken models is very beneficial for the developmental researches. Fertile eggs are cheap, easy to find at stores and only an incubator is required for their development (Smith and Nagy, 2008). The shell can easily be fenestrated to view or manipulate the embryo directly. It can also be easily obliterated so that to continue the development process (Smith and Nagy, 2008). Maternal metabolism lacks an *in ovo* system that allows the direct isolation of teratogenic effects. All in a nutshell, the embryo model offers a cheap and practical system in which it is possible to apply modern experimental tools to know how a teratogen interferes with specific mechanisms underlying the organogenesis and the morphogenesis (Drake et al., 2006).

Hence, the aim of this work is to study the teratogenic effect of the *in ovo* exposition to ethanol on the osteogenesis in a system of a chicken-embryo model considering the injected ethanol dose and the embryonic development stage.

MATERIALS AND METHODS

Ethical approval

The experiment was carried out according to the National Regulations on Animal Welfare and Institutional Animal Ethical Committee.

Experimental design

Present investigation was carried out on a group of 49 embryonated of the broiler chickens (Hubbard F15) eggs, brought from the private hatchery “Coopérative agricole Errakhaà Wa Izddihar”, located in Theniyetsaida (Ain Yagout – Batna) through the period from April 2017 to March 2018, Algeria. The eggs were divided into three groups: a non-treated negative control group (n=7), a positive control group, treated with distilled water, and which, in turn, was subdivided into three subgroups of six eggs each. These subgroups received respectively (20, 40 and 80 µl) of distilled water. A last group, exposed to ethanol 33%, was also subdivided into three subgroups of eight eggs each. These subgroups received respectively (20, 40 and 80 µl) of ethanol 33% (Table 1).

Substance injection

This particular step is crucial and necessitates a maximum sterility. Hence, a Bunsen burner was used for the substance injection in the air sacs (Cevik et al., 2007).

Incubation

The eggs were incubated during 240 hours (10 days) in a humid incubator at 37°C and 60-65% of humidity, and were automatically turned every four hours (Cevik and Lale Satiroglu, 2003; Aguilera et al., 2005).

Visualisation of the skeleton

The skeletal staining was done by the technique described by Sadeghi (2014): the embryos were eviscerated and the skeletons were cleared without being damaged. After that, they were fixed in ethanol absolute. The skeletal staining was done with Alizarin red at 0.001 %. The samples were then rinsed by KOH at 1%, 3 times during a week. The last step was the treatment of the samples with ascending concentration sets of glycerol in KOH at 1% during 24 hours in every step. Finally, the samples were placed in glycerol.

Histological examination

The samples were fixed with 10% buffered formalin, passed through to a series of ethanol from 80% to 100%, then cleared with xylene during one hour in each shower and then incorporated in paraffin. 5 µm bone sections were taken by a microtome (Leica), the slides were then H&E stained and analysed under an optic microscope Carl Zeiss Axioskop 20 connected to a digital video camera DOM 300 (Laanani et al, 2015; Khenenou et al, 2017; Khenenou et al, 2019).

Table 1. Treatments, subgroups and number of eggs in each group of study

Group	Treatment	Subgroup	Number of eggs
A : Negative control	No treated		7
B : Positive control	Distilled water	B1: 20 µl	6
		B2: 40µl	6
		B3: 80 µl	6
C : Treated; ethanol (33%)	EtOH (33%)	C1: 20 µl	8
		C2: 40 µl	8
		C3: 80 µl	8

Statistical analysis

The statistical analysis of the experimental data was carried out using statistical software Graph Pad Prisme 5.01. The data concerning the length of the proliferation and hypertrophic zones were identified using a T test for 2 independent samples or an analysis of the one-way variance (One-way ANOVA); for both tests. P<0.05 was considered as statistically significant between the control groups and those exposed to ethanol.

RESULTS AND DISCUSSION

Ethanol effects on the embryonic viability

Present findings indicated that the *in ovo* injection of the distilled water at low quantities (20µl) had a negligible effect on the embryonic viability whose average embryo survival rate was 83.33%; only a slight difference was noticed in comparison to the control group (85.72). In contrast, it was noticed a remarkable diminution of the embryonic (58.33%) viability at higher water quantities (40 and 80µl). When the groups exposed to ethanol 33%, it was noticed a diminution of the embryo viability rate depending on the volume (the bigger the volume gets; the more the embryo mortality is), the average of the survival rate of embryos treated with 20µl was 56.28%, but with an increase of the injected amount reaching 40µl and 80µl, the average of the survival rate was reduced to 37.5% and 12.5% respectively (Table 2). The data illustrated in table 1 and figure 1 indicated that ethanol affects the embryonic survival rate at an early stage. Present results are in complete concordance with the study done by Zulifqar et al. (2015) which demonstrated that the treatment of the chicken embryos at early stages causes a decrease in the survival rate of chicken embryos.

Table 2. Average of survival rates in broiler chicken embryos treated with ethanol

Group \ Quantity (µl)	20	40	80
Negative control ; no treated	85.72%	85.72%	85.72%
Positive control; distilled water	83.33%	58.33%	58.33%
Treated; ethanol	56.28%	37.50%	12.50%

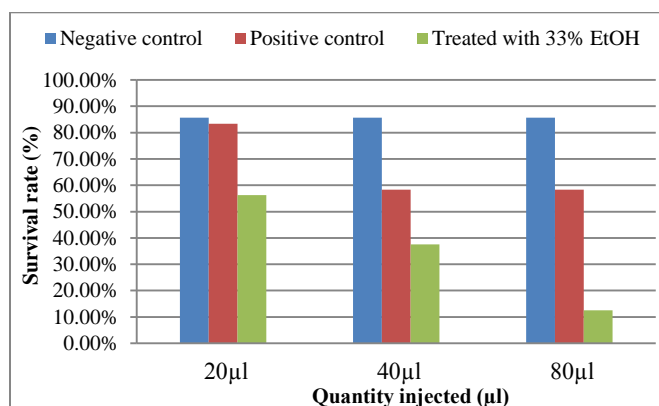


Figure 1. The effect of ethanol on broiler chicken (Hubbard F15) embryo survival rate, Algeria (April 2017 to March 2018).

Special staining

The stereomicroscopic observation of the embryos stained with Alizarin red has shown a dark red stain noticed on the long bones (Figure 2); Alizarin red staining has an affinity for calcium ions. This explains that there is an ossification process at the level of these bones. Hence, it was noticed that the ossification of long bones, such as the humerus bone, starts on the 10th day of incubation for chicken embryos. This confirms the study done by Sawad et al. (2009).

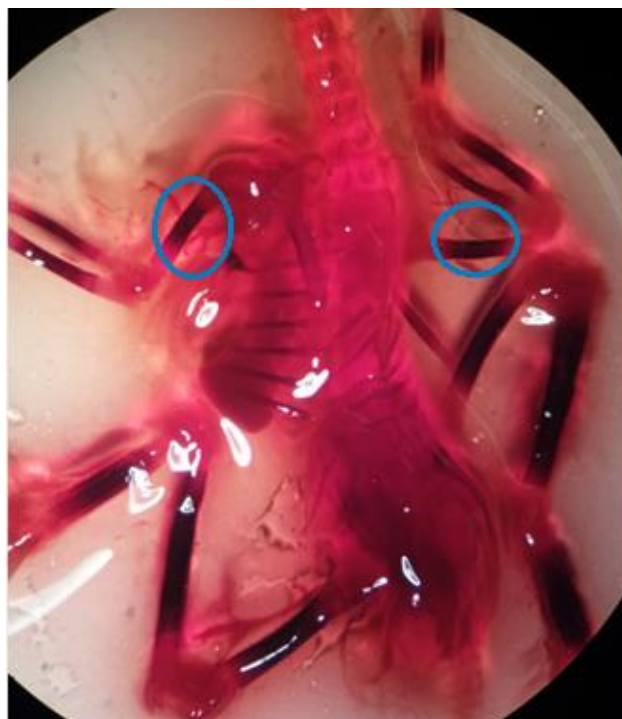


Figure 2. A broiler chicken (Hubbard F15) embryo after 10 days of staining with Alizarin red, Algeria (April 2017 to March 2018).

The effect of ethanol on the length of the proliferation and cartilaginous-hypertrophy zones

Long bones like the humerus bone develop by endochondral ossification, length measurements of the proliferation and cartilaginous-hypertrophy zones, particularly of the developing humerus bone, show the results below:

The length of the humerus-bone's proliferation zone of chicken embryos of the negative control group ($515.7 \pm 1.28 \mu\text{m}$, $n = 4$) was considerably ($P < 0.005$) larger than that of the three groups exposed to ethanol (20µl, 40µl and 80µl) whose lengths are ($505.9 \pm 1.14 \mu\text{m}$, $498.1 \pm 1.93 \mu\text{m}$ and $489.9 \pm 0.83 \mu\text{m}$) respectively (Figure 3). Also, the cartilaginous-hypertrophy zone of the humerus bone of the control group ($543.2 \pm 0.98 \mu\text{m}$, $n=4$) was

considerably ($P < 0.005$) superior to that of the three groups exposed to ethanol (20 μ l, 40 μ l and 80 μ l) whose length is ($523.4 \pm 1.15 \mu$ m, $515.5 \pm 0.88 \mu$ m, and $493.9 \pm 2.84 \mu$ m) respectively (Figure 4).

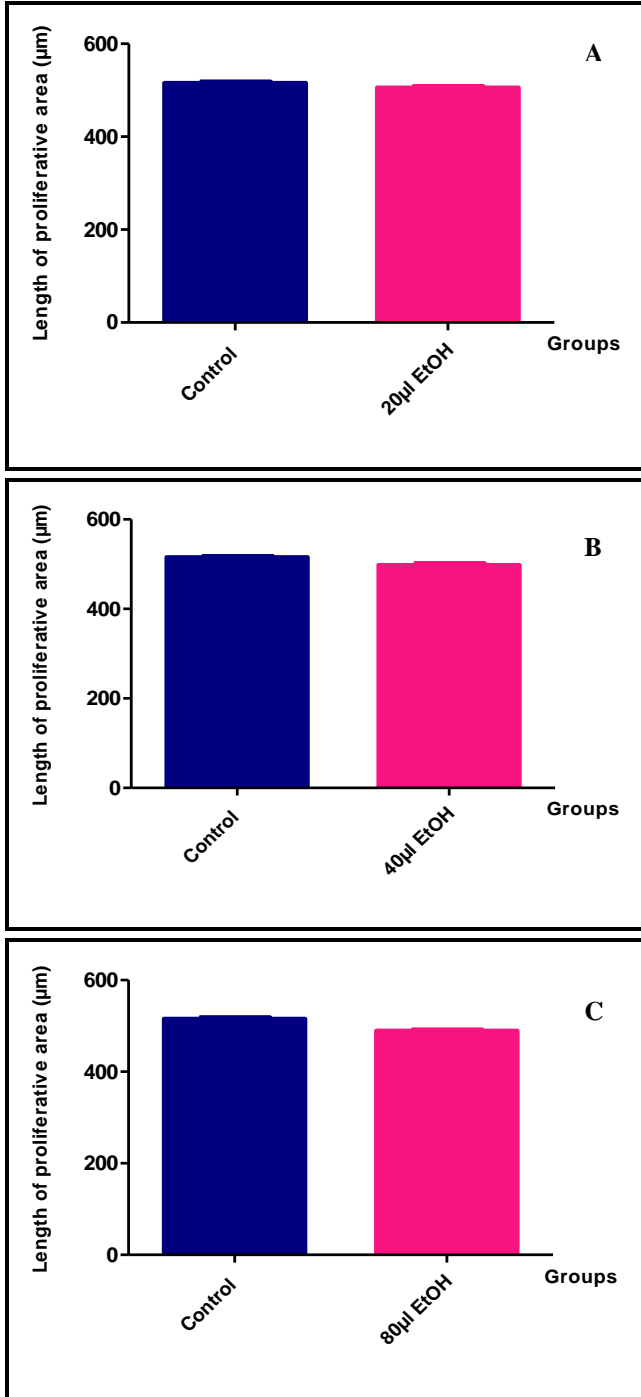


Figure 3. The ethanol effect on the length of the proliferative zone of the humerus of the broiler chicken (Hubbard F15) embryo, Algeria (April 2017 to March 2018) **A.** Exposition at 20 μ l of EtOH, **B.** Exposition at 40 μ l of EtOH, **C.** Exposition at 80 μ l of EtOH.

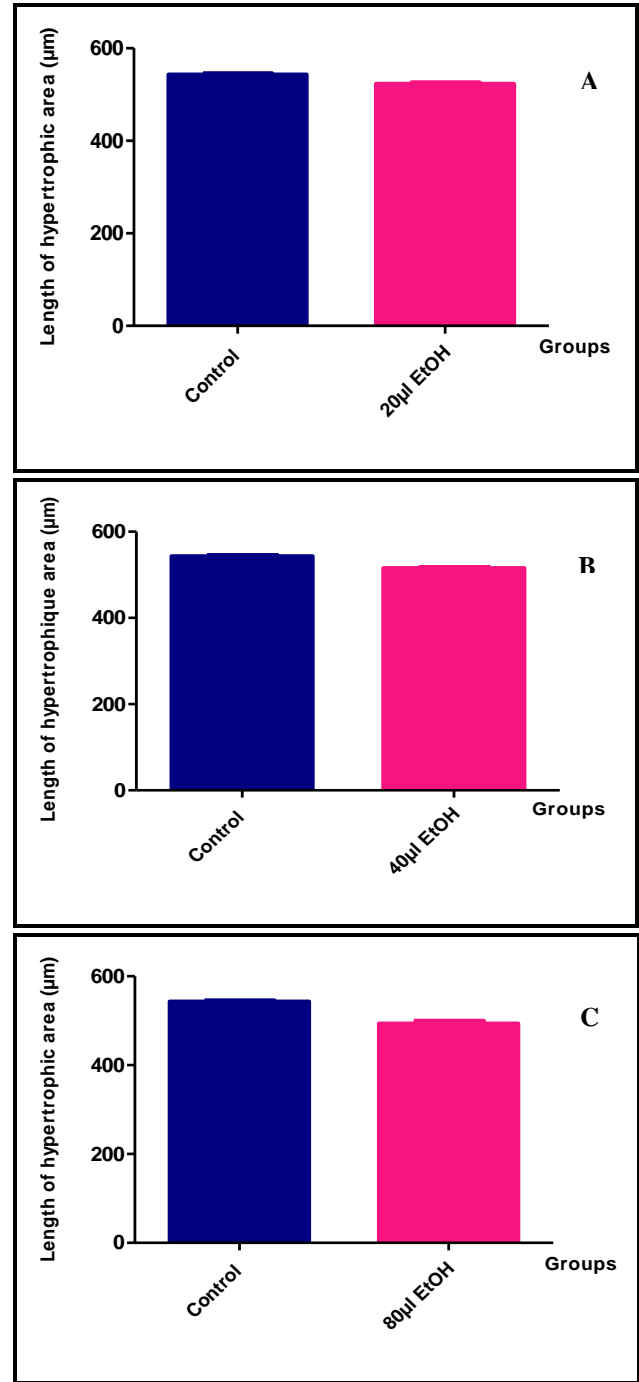


Figure 4. The ethanol effect on the length of the hypertrophic zone of the humerus of the broiler chicken (Hubbard F15) embryo, Algeria (April 2017 to March 2018); **A.** Exposition at 20 μ l of EtOH; **B.** Exposition at 40 μ l of EtOH; **C.** Exposition at 80 μ l of EtOH.

Present results demonstrated that exposure to ethanol, causing skeletal disturbances, affects on long bones by delaying ossification and total bone length which already reported by Clissmann and Brennan (2017).

Present results revealed that ethanol inhibited the cell proliferation and the cartilaginous-hypertrophy process. This may have shortening effects on the proliferation and the cartilaginous-hypertrophy zones, because it was noticed that, at high ethanol concentrations, the length of the two zones of proliferation and cartilaginous hypertrophy of the humerus bone was considerably shortened.

Many studies were performed to determine the toxic effects of naturel and synthetic products on the embryos of chickens, including the studies undertaken by Afzal *et al.* (2019); Chaudhuri (2019) and Patel *et al.* (2019). Although the present research was planed base on chemical products that used in pharmaceutical production and considered as a less expensive and good antiseptic (Presterl *et al.*, 2019).

The exposition to ethanol indicated the ossification process of chicken embryos in a dose-dependent manner. Therefore, it can be understood that the exposition to ethanol delays the skeletal development of chicken embryos at gastrula stage by repressing osteogenesis. Furthermore, ethanol effects on osteogenesis seem to be dose dependent, which has already been demonstrated by Zhong-yang *et al.* (2016).

CONCLUSION

Present findings indicated that ethanol is harmful and directly affects the embryonic viability. Also, it is noticed that exposition to ethanol at early stages causes a decrease in the survival rate of embryos in a dose-dependent manner. The embryos exposed to ethanol have indicated a delay in the skeletal development by a shortening of the length of the proliferation and cartilaginous-hypertrophy zones. This effect is considerable at higher doses. In conclusion, ethanol has negative effects on the embryonic development; these include a delay in the growth and skeletal anomalies.

DECLARATIONS

Competing interests

The authors have no competing interests to declare.

Consent to publish

All authors gave their informed consent prior to their inclusion in the study.

Author`s contributions

Boussouar , Khenenou and Bennoune were involved in the collection of data, statistical analysis and drafting of

the manuscript. Khenenou and Bennoune read and approved the final manuscript.

REFERENCES

- Aguilera Y, Dorado ME, Prada FA, Martinez JJ, Quesada A and Ruiz-Gutiérrez V (2005). The protective role of squalene in alcohol damage in the chick embryo retina. *Experimental eye research*, 80: 535-543. DOI:10.1016/j.exer.2004.11.003
- Afzal G, Ali S, Kiran S, Mustafa G, Ahmad H I, Hameed S and Majeed J (2019). Toxicological effect of ethanol on the development of chicken embryo in ova. *Pure and Applied Biology*, 8(1): 882-892. DOI:http://dx.doi.org/10.19045/bspab.2019.80030
- Bupp Becker SR and Shibley Jr IA (1998). Teratogenicity of ethanol in different chicken strains. *Alcohol and alcoholism*, 33(5):457-464. DOI :https://doi.org/10.1093/alcalc/33.5.457
- Cevik TA and Lale Satiroglu-TN (2003).The Effect of Ethanol Exposure on Extraembryonic Vascular Development in the Chick Area Vasculosa. *Cells Tissues Organs*, 175:84-97. DOI: 10.1159/000073752
- Cevik TA, Gulcin A, Ilgaz A, Deniz E and Candan O (2007). The effect of *in ovo* ethanol exposure on retina and optic nerve in a chick embryo model system. *Reproductive Toxicology*, 23: 75-82. DOI:10.1016/j.reprotox.2006.09.006
- Chaudhuri JD (2004). Effect of a single dose of ethanol on developing skeletal muscle of chick embryos. *Alcohol*, 34: 279-283. DOI: 10.1016/j.alcohol.2004.07.012
- Chaudhuri JD (2019). Effect of a single dose of ethanol on developing peripheral nerve of chick embryos. *European Journal of Anatomy*, 10(2): 53-60.
- Clissmann D and Brennan D (2017) .Skeletal examination in a chick embryo model of fetal alcohol syndrome indicates impaired osteogenesis .*Reproductive Toxicology*, 72:33-34. DOI:10.1016/j.reprotox.2017.06.145
- Drake VJ, Koprowski SL, Lough JW and Smith SM (2006). Gastrulating chick embryo as a model for evaluating teratogenicity: a comparison of three approaches. *Birth defects research (Part A)*, 76: 66-71. DOI: 10.1002/bdra.20202
- Kamran K, Khan MY and Minhas L (2011). Teratogenic effects of ethanol vapour exposure on chick embryos. *Journal of the Pakistan medical association*, 61:328.
- Khenenou T, Boughrara M, Melizi M and Lamraoui R (2017). Histomorphological study of the bursae of Fabricius of broiler chickens during gumboro disease in Algeria area. *Global veterinaría*, 18(2):132-136. DOI:10.5829/idosi.gv.2017.132.136
- Khenenou T, Berghiche A, Rahmoun DE, Miloudi A and Athamna H (2019). Morpho-histological comparisons of liver between the broiler chickens and wild boar in Algeria. *Advances in animal and veterinary sciences*, 7(1): 24-29. DOI:http://dx.doi.org/10.17582/journal.aavs/2019/7.1.24.29
- Laanani I, Alloui N, Bennoune O, Laabaci W, Ayachi A and Benterki M S (2015). Clinical and histopathological

investigations on inclusion body hepatitis in chickens in the Ain Touta area (Algeria). *Global journal of animal scientific research*, 3(1):72-76.

- McGill J, Meyerholz D K, Edsen-Moore M, Young B, Coleman R A, Schlueter A J, Waldschmidt T J, Cook R T and Legge K L (2009). Fetal exposure to ethanol has long-term effects on the severity of influenza virus infections. *The journal of immunology*, 182: 7803-7808. DOI: 10.4049/jimmunol.0803881
- Miller Jr RR, Heckel CD, Koss WJ, Montague SL and Greenman AL (2001). Ethanol- and nicotine-induced membrane changes in embryonic and neonatal chick brains. *Comparative Biochemistry and Physiology, Part C*, 130: 163-178. PII: S 1 5 3 2 - 0 4 5 6 Ž 0 1. 0 0 2 2 7 - 7
- Patel S, Jana S, Chetty R, Thakore S, Singh M and Devkar R (2019). Toxicity evaluation of magnetic iron oxide nanoparticles reveals neuronal loss in chicken embryo. *Drug and chemical toxicology*, 42(1): 1-8. DOI: <https://doi.org/10.1080/01480545.2017.1413110>
- Presterl E, Diab-El Schahawi M, Lusignani LS, Paula H and Reilly JS (2019). Basic Principles and Introduction to Disinfectants and Antiseptics for Skin, Mucosa, and Wounds. In *Basic Microbiology and Infection Control for Midwives*, Springer, Cham pp. 51-57.
- Sadeghi F (2014). Two separated protocols with the most important comments for skeletal staining in embryonic and adulthood period in laboratory animals. *Research papers*, 11(2).
- Sawad AA, Balsam AH and Al-Silawi AN (2009). Morphological study of the skeleton development in chick embryo (*Gallus domesticus*). *International journal of Poultry science*, 8(7):710- 714. DOI: 10.3923/ijps.2009.710.714
- Smith S M and Nagy L E (2008). The avian embryo in fetal alcohol research Alcohol: Methods and protocols. Humana Press, 447: 75-84. DOI:10.1007/978-1-59745-242-7_6
- Zhong-yang L, Zheng-lai M, Wen-hui L, Xin C, Jian-long C, Xiao-Yu S, Manli C, Kenneth K H L and Xuesong Y (2016). Ethanol exposure represses osteogenesis in the developing chick embryo. *Reproductive Toxicology*, 62: 53–61. DOI: <https://doi.org/10.1016/j.reprotox.2016.04.020>
- Zulifqar AL, Ayaz AS, Baradi W, Zameer AP, Khalid HL, Ghulam M M, Gulshan A S and Tahira J U (2015). Effects of a single dose of ethanol on survival rate and angiogenesis of chick embryo. *Animal and Veterinary Sciences*, 3(1): 8-11. DOI: 10.11648/j.avsc.20150301.12